



A Patient's Viewpoint of Cataract and Retinal Detachment Surgeries

A. Terry Bahill^{1*} and Patrick J. Barry²

¹Systems Engineering, University of Arizona, 1622 W. Montenegro, Tucson AZ, 85704-1822, USA.

²Envision Eye Care Center, Tucson Arizona, USA.

Authors' contributions

This work was carried out in collaboration between all authors. Author ATB designed the study, performed the statistical analysis, wrote the protocol and wrote the first draft of the manuscript. Author PJB provided the medical instruments, measurements, clinical images and medical expertise. All authors read and approved the final manuscript.

Original Research Article

Received 21st September 2013

Accepted 8th May 2014

Published 4th June 2014

ABSTRACT

Aims: The purpose of this paper is to (1) describe the changing details of a complex medical case study from the patient's view allowing the reader to continually evaluate complications resulting from cataract and retinal detachment surgeries, (2) explain good and bad aspects of communications between patients, optometrists, ophthalmologists and systems engineers and (3) show a patient's view of a detaching retina.

Methodology: This paper was written from the patient's point of view of the interactions between the patient, the optometrist and the ophthalmologists during a dozen eye surgeries for cataracts and retinal detachments. It was excerpted from the patient's notes (including test results, charts and images), surgical reports, letters to the doctors and their referral reports. This paper was written in the first person singular and in chronological order. This should help the reader to see changes in the interactions of the symptoms and treatments from ocular surgeries in a multifaceted medical example.

Results: This paper has documented malplacement of an intraocular lens, ignoring patient's complaints of pain, lack of explanation of what the subject should expect after retinal detachment surgery (such as strabismus, diplopia, pain, wrinkled retina, and dynamic visual changes due to gas bubble absorption), lack of explanation for the subject's potential visual acuity defects and color deficiencies, poor communication between patient care specialists about these defects, lack of knowledge by technicians

*Corresponding author: E-mail: terrybahill@outlook.com;

using ophthalmological instruments, lack of documented processes for using these instruments (which means different technicians used the instruments differently), lack of proper medical care due to physician overload (i.e. scheduling more than 60 patients per day per physician), and ignoring the patient's complaints of pain. While reading this paper, the reader should accept or challenge each of these assertions.

Conclusions: Pain is hard to diagnose, measure, quantify and treat, making it frustrating for both the patient and the physician: in this case, there were many causes of the pain, which caused confusion. For the last six years, this patient complained about ten specific symptoms, which were treated individually: treating this case as a system of interacting problems led to a better understanding and resolution.

Keywords: Cataract surgery; scleral buckle; communication; complications; retinal detachment; detaching retina; ocular pain; quality of life; retina surgery; lessons learned; peeling of the inner limiting membrane; color blind.

ABBREVIATIONS

ILM Inner Limiting Membrane; IOL Intraocular Lens; MRI Magnetic Resonance Imaging; OCT Optical Coherence Tomography; OS Left eye; OD Right eye; RD Retinal Detachment; RPE Retinal Pigment Epithelium.

1. INTRODUCTION

1.1 Who Should Read This Paper and Why Should They Read It?

1.1.1 Ophthalmologists

Ophthalmologists can read this paper and continually diagnose the patient's medical problems in their minds. The patient's symptoms and the interactions of people have been laid out in chronological order. These are the facts that were thought to be true at the time, but some of them might prove to be wrong in the end. The reader can use this information to understand one patient's confusion. The appendix provides useful but possibly irrelevant statistics that he/she might want to consider. Hopefully, the ophthalmologist can gain an appreciation of the patient's viewpoint of ocular surgeries. The ophthalmologist could learn about the types of pain that can result from ocular surgeries and use this information to write brochures and computer animations that describe potential postoperative pain and explain treatments that could be used to resolve those pains. Finally, the ophthalmologist can decide what he/she would have done differently than these ten ophthalmologists did.

1.1.2 Optometrists

Optometrists can expand their horizons and find their place in ocular surgeries. In 1977, Larry Stark et al. [1] described many nontraditional optometry tasks that professionals were performing in his Neuro-optometry Clinic at Berkeley (UC) and San Francisco (UCSF). This paper suggests another nontraditional task: assisting patients with detaching retinas. Detached retinas seem to be in the purview of ophthalmologists. However, this paper explains ways that an optometrist was involved in (1) diagnosing a detaching retina, (2) tracking the specialties and equipment of local ophthalmologists, (3) acting as a primary visual care provider, (4) understanding and explaining to the patient what lies in store for him

during and after the surgery, (5) diagnosing and perhaps solving postoperative complications {such as (a) postoperative diplopia, which (in this case) was ameliorated with prism spectacles, (b) the iris being trapped by the intraocular lens, which was solved by a lens replacement, (c) inflammation, in this case due to the suture securing the scleral buckle and (d) helping with pain diagnosis and remediation,} and (6) explaining the relationships between fundus photos, visual field diagrams and ocular coherence tomography images. The American Optometric Association also has an extensive set of recommendations for optometrists dealing with retinal detachments [2].

1.1.3 Students of ophthalmology and optometry

Students of Ophthalmology and Optometry can augment their diagnostic skills by practicing on this real-lifetime-sequential case study. In addition, they can learn about a topic that does not get much attention in the curriculum, namely pain.

1.1.4 Patient advocates

Intelligent laymen, patient advocates and patient advisors can learn about complications and interactions between cataract and retinal detachment surgeries, such as the following. Pain is hard to diagnose, measure, quantify and treat, making it frustrating for both the patient and the physician: in this case, there were many causes of the pain, which caused confusion. There was no face-to-face communication between the dozen doctors that were involved in this case: furthermore, many times the written communications were not received, read or understood. In complicated procedures involving many physicians and many physical systems, perhaps there should be a patient's advocate, who knows the system and is interested only in the patients' best interests.

1.1.5 Families and friends

Families and friends of patients who have or will undergo ocular surgeries can understand what the patient is experiencing and what signs and symptoms should be reported to the ophthalmologist. When a new clue surfaces, this group has to answer difficult questions such as, Should we call the doctor now? Should we go to the emergency room? Should we take more narcotic pain pills? Should we wait until the morning? Reading this paper should augment the written instruction given by the surgeon and thus help with these decisions.

1.1.6 "We learn from our patients"

Sir William Osler (physician, educator, philosopher and author) captured this nugget of knowledge with, "He who studies medicine without books sails an uncharted sea, but he who studies medicine without patients does not go to sea at all."

2. HISTORY/METHODS/RESULTS

A. Terry Bahill (ATB) has had a dozen eye surgeries over the last half-dozen years. He has been examined and treated by an optometrist and ten ophthalmologists. The following report is his description of the interactions between these vision care specialists. This paper describes (1) cataract and retinal detachment surgeries and their after effects (including many images from the patient's viewpoint, which have never before been presented in the literature), and (2) quality of life measures.

This section was written by ATB about his eye surgeries. Other patients will have different numbers and details, but the overall processes should be about the same. This section is written from the patient's point of view of the interactions between the patient, the optometrist and the ophthalmologists during eye surgeries for cataracts and retinal detachment. Therefore, this section is written in the first person singular. It was excerpted from my notes, surgical reports, my letters to the doctors and their referral reports. Nothing was retrospectively edited. So it is possible that at one time I wrote something in my journal that was different from something that I had written at another time: I did not edit out these contradictions. Oscillations in my health and mood may be apparent. This case is multifaceted with many complications. The ten ophthalmologists are identified as "Ophthalmologist-1" to "Ophthalmologist-10."

2.1 May 24, 2007, First Cataract Operation

It all started on a beautiful May morning in Tucson. Ophthalmologist-1, assisted by his wife (the anesthesiologist) and a surgical nurse, performed a cataract extraction and lens implant on my left eye. It was a quiet relaxed atmosphere where they were describing to the nurse their upcoming vacation to Italy. Ophthalmologist-1 was doing hydrodissection in the membrane capsule, when he suddenly said, "Whoops. What was that?" He wrote in his surgical report, "the posterior capsule had torn as a result of the hydrodissection... It was elected to insert an [available] MA60AC lens rather than the [selected] one-piece acrylic lens." Kenalog was not used to assist the partial anterior vitrectomy. That evening, the next morning and the next afternoon, I told his staff that I was in pain.

2.2 May 25, 2007, Follow-up Exam

I told Ophthalmologist-1 that the eye hurt and that I was seeing many floaters. As he was examining the operated eye, he said that in order to compensate for the ruptured posterior capsule, he removed some of the vitreous (which pulled on the retina), placed the lens (a square edged, 3-piece posterior chamber intraocular lens (IOL), Alcon model MA60AC) more anterior than planned (in the ciliary sulcus), and put a suture in the cornea. Later he said that rupture of the posterior membrane capsule was a rare event, happening to only one of his other patients 17 years ago. See the appendix for statistics from the literature.

2.3 May 26, 2007, Saturday, Pain in the Eye

My left eye hurt. It was tearing and bloodshot. Ophthalmologist-1 was on vacation in Italy. I called a friend, Ophthalmologist-2, and told him that my eye hurt and I could not contact Ophthalmologist-1 or his backup. He said that pain after a cataract operation most certainly means infection. He advised me to go to the emergency room. Ophthalmologist-3 (who by coincidence was the backup in Ophthalmologist-1's practice and also the ER ophthalmologist on call) gave me a prescription for Vicodin (hydrocodone). It did not relieve the pain. I saw him another four times in the next two weeks. With his slit lamp, he never saw inflammation within the eye (endophthalmitis): so he said that he did not know why there was severe pain. In a four-month follow-up exam, ophthalmologist-1 used a Snellen chart to assess my visual acuity. He dismissed my complaints of pain and he never looked at the placement of the IOL haplets: we do not know if he had instruments to do so. For the next four years at every medical exam with my ten ophthalmologists, I complained about pain in the front of the eye. Table 1 shows that nothing relived this pain.

Table 1. Since 2008, at various times, ATB has taken the following anti-pain drugs. None relieved the pain in the brain

Generic name	Strength	Brand name	Dosage
Ibuprofen	200mg	Motrin®	16 pills per day
Hydrocodone/APAP	5/500mg	Vicodin®	6 pills per day
Oxycodone/APAP	5/325mg	Percocet®	6 pills per day
APAP is an abbreviation for acetaminophen		Tylenol®	

2.4 May 8, 2008, One Year Later

I saw a static, 100-degree diameter¹, $\frac{3}{4}$ ring (two degrees thick) of bluish light for maybe a half minute in left eye with the eye open. It looked like Fig. 1 (top-left). The dark green disk represents the subject's field of view. That event was probably caused by the vitreous (the jelly in the eyeball) detaching from the retina. Please note that this is the visual experience of one subject. The literature more often describes a detaching vitreous with spider webs and lightning bolts.

Note added in 2013: Both moving the lens forward and removing some of the vitreous gel would move the vitreous forward, and pull on the retina. This sequence can lead to a retinal tear and a detachment, especially during the first year after surgery. "If the cataract surgery is complicated with a capsular rupture, the risk increase for RD [retinal detachment] is ten-fold." It is a shame that I did not know that in 2008.

2.5 May 12, 2008, First Detached Retina Operation

The optometrist saw half-dozen retinal tears and referred me to a retina specialist, Ophthalmologist-4. He told me that the operation had a 92% chance of success and if it did fail, he could perform a second operation that had a 50% chance for success. {For more statistics like these, the reader should go to the appendix.} He scheduled an operation for that evening. During that operation, he put a scleral buckle around the eyeball, removed the vitreous humor (vitrectomy), repaired the retinal tears with freezing (cryopexy) and with an endolaser, and inserted a bubble of perfluoropropane (C_3F_8) gas (also called octafluoropropane). My double vision (diplopia) started after this surgery. The next day, and on other visits, I complained about inflammation, a blood shot eye, foreign body sensation (like an eyelash trapped under the eyelid), pain in the front of the eye and now pain behind the eye.

2.6 Explanations of Some Technical Terms

I had arhegmatogenous (rhegma=rent or fissure)retinal detachment, which means tears (like tears in a fabric, not like tears when a person is crying) in my retina allowed fluid to leak underneath the retina, thus detaching it from the choroid (the vascular layer of the eye lying between the retina and the sclera, the white part of the eyeball). The tears were probably caused by the detaching vitreous (the jelly in the eyeball that is attached to the retina at

¹In this paper, the size of the visual angle will be given in degrees of arc or angular size, because it is easy to estimate. For example, the clinical fovea (one degree in diameter) is the width of the fingernail on the little finger at arm's length and a fist is a little less than ten degrees wide. For comparison, the sun and the moon are $\frac{1}{2}$ degree in diameter [3].

several places). Ophthalmologist-4 decided to use several common retinal repair techniques: scleral buckling, photocoagulation, vitrectomy and injection of a bubble of perfluoropropane. Simplistically, a scleral buckle is a band of silicone that is sutured around the eyeball under the extra ocular muscles. It buckles the eyeball pushing certain regions closer to the retina. Laser photocoagulation and freezing create scar tissue that attaches the retina to the choroid. In a vitrectomy, the jelly-like vitreous humor is removed. Pars plana vitrectomy describes a particular pathway (through the pars plana) that the surgeon uses to remove the vitreous. Next, the vitreous chamber (the big hollow chamber in the middle of the eye) is filled with a bubble of about 15% perfluoropropane (C_3F_8) gas (the other 85% is just air). This bubble blocks fluid in the eye from passing through the tear and under the retina. This allows the choroid to pump the fluid out of the sub retinal space and this in turn allows the retina to reattach to the choroid. With a gas bubble in your eye, you cannot fly in an airplane (or do anything else that would rapidly change the pressure around you).

Typically, ophthalmic lasers for retinal photocoagulation use Nd:YAG crystals to produce green laser light with a wavelength of 532nm or semiconductors to produce yellow light with a wavelength of 577nm. The choice is based on absorption spectra of the ocular media. For example, green light has excellent absorption by melanin and hemoglobin with little absorption by xanthophyll. Whereas, yellow light has the same good absorption by melanin and hemoglobin, but in addition it has no absorption by xanthophyll. Yellow light scatters less in the optic media; therefore, yellow lasers can operate with lower power. Operating parameters have wide variations; for example, power varies from 50 to 1000mW, pulse duration varies from 10 to 200ms, spot size varies from 50 to 500 μ m, and duty cycle varies from 15% to 100%.

The human visual field comprises the images that the subject can see with the eye looking straight-ahead (primary position): typically, this is 90° temporal, 55° nasal, 50° up and 70° down, as shown in Fig. 3.

Concerning cataract operations, the human crystalline lens is enclosed in a capsule. This is sometimes referred to as the membrane capsule, a capsular bag, or a lens *capsule*. The front and backsides are referred to respectively as the anterior capsule and the posterior capsule.

Throughout May and June, my vision was improving. However, I was surprised by the tropia: when at rest, my left-eye images were about ten degrees up, ten degrees to the right and five degrees cyclorotated with respect to the right-eye images. I could not fuse the right and left eye images. This tropia was caused by the scleral buckle. Ophthalmologist-4 did not prepare me for this.

2.7 June 29, 2008, Gas Bubble Disappears

Ophthalmologist-4 had told my wife and me to be patient for six weeks, or until the gas bubble disappeared, then we would be out of the woods for further complications. Therefore, on this Sunday, we were in high spirits, because this was six weeks after the operation and the gas bubble was finally absorbed.

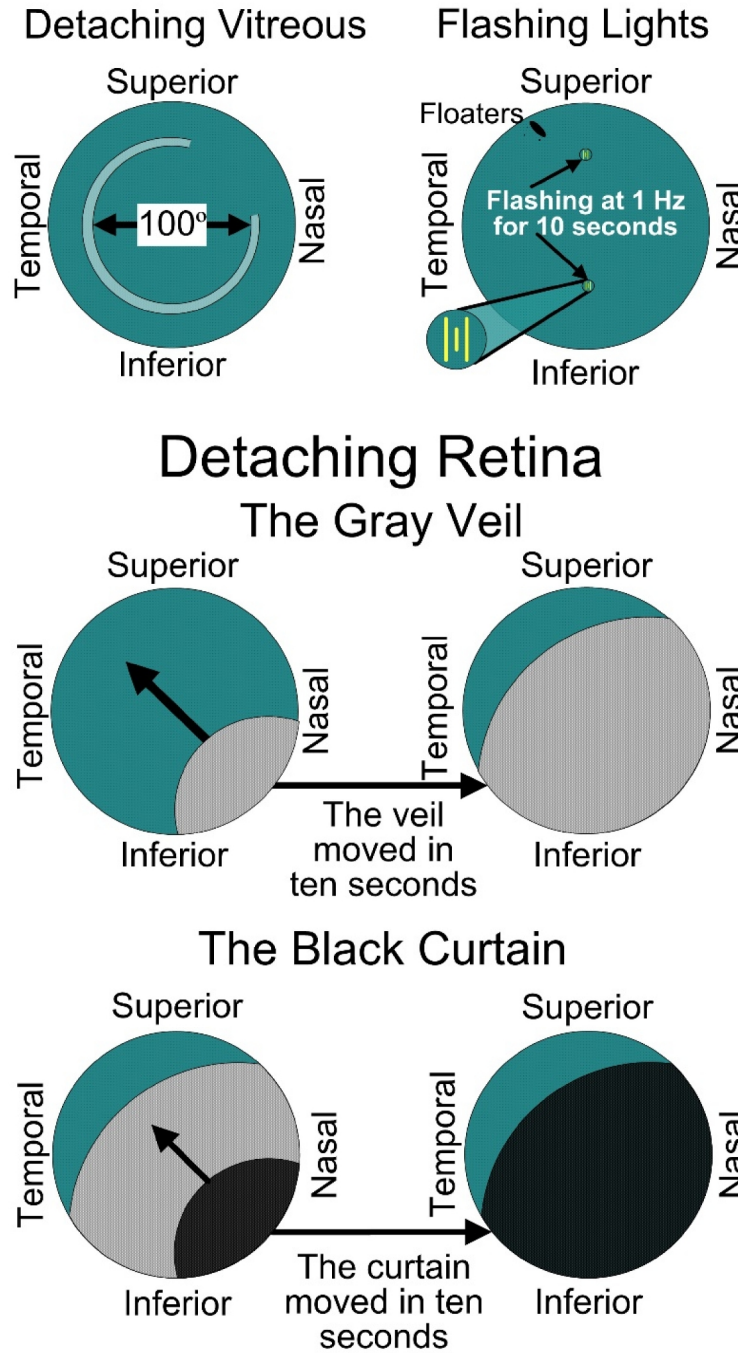


Fig. 1. Temporal sequence from the patient's viewpoint of the left eye's retina detaching. Top-left: The vitreous detaching. The blue-green disk represents the subject's field of view. Top-right: Floaters and flashing lights caused by the retina detaching. Middle: The gray veil started in the lower-right visual field and progressed to the upper-left. Bottom: The black curtain followed the same path as the gray veil

2.8 June 30, 2008, Retina Detaching

At 10:00 AM, Ophthalmologist-4 saw a small hole in the retina, as well as a scab on the retina. He scheduled an operation for 3 PM the next day. Four hours later, I saw vertical yellow lines about two degrees long and one degree apart: three on top of my field of view and three on the bottom. See Fig. 1 (top-right). They flashed at one hertz for about ten seconds. Later I saw big black floaters². Then a convex gray veil (with a radius of curvature of around 40°) moved from the lower-right to the upper-left across my field of vision as shown in Fig. 1 (middle row): this took around ten seconds. Then, a few minutes later, a convex black curtain moved across my retina and eclipsed 80% of my field of vision, Fig. 1 (bottom row). I called Ophthalmologist-4, told him my symptoms and he confirmed that the macula of my retina had detached and we would do the operation the next day, as scheduled. I was not a happy puppy: since the retinal detachment operation, they would not let me drink beer, work on the computer for more than 15 minutes at a time, or go out of the house for more than an hour a day. I had to lie on my side for most of the day. (I did not have to lie in prone position, because my retinal tears were mostly in the upper-left part of the eyeball.) My primary care physician had prescribed Sertraline for depression. I did not take measurements of the recovery from this first retinal detachment operation, because I had no idea of what to expect. So I could not plan an experiment.

Note: this is the visual experience of one subject. The literature most often describes the detaching retina with spider webs, twig-like objects in the line of vision, flashing lights, lightning bolts, sparkling dots, fireflies, fireworks or sparks.

2.9 July 1, 2008, Second Detached Retina Operation

Ophthalmologist-4 pushed the macula back into place, zapped the retina with his laser and inserted another gas bubble. An intraocular gas bubble prevents aqueous liquid from contacting the retinal tear and sneaking under the retina. This barrier permits the choroid to remove sub retinal fluid and shelters the tear until a choroid-retinal scar is formed, sealing the break. A bubble of perfluoropropane (C_3F_8) gas will gradually be absorbed into the blood stream and will be replaced by aqueous fluid, which is continually produced by the ciliary body. This process will take three to ten weeks, depending on how big the bubble is and other things. The first objects that I saw as the gas was absorbed were stars in the sky as shown in Fig. 2. Obviously, I was outdoors at night looking straight ahead.

Because of the difference in the index of refraction of liquid and gas, light rays that go through the gas bubble scatter before they reach the retina. Only rays going through the aqueous fluid can reach the retina in focus, as shown in Fig. 2. As a patient, this came as a surprise to me. Next, as the gas was being absorbed into the blood via the retina and choroid, the bubble changed its size and shape [4,5].

²Floaters are small clumps of cells, pigment or gel that "float" inside the vitreous. They have a wide variety of sizes and shapes. For me they are often black circles tenths of a degree in diameter. Sometimes they move, seemingly like a house fly. Floaters may appear as small specks, hair-like objects, clouds, strings, streaks, dots, dust or spider webs moving in front of a person's field of vision. They are especially apparent when looking at a plain white background or a blue sky. Due to a lack of depth perception, a bug on my monitor looks like a smudge in my drawing and it takes some time to resolve the issue.

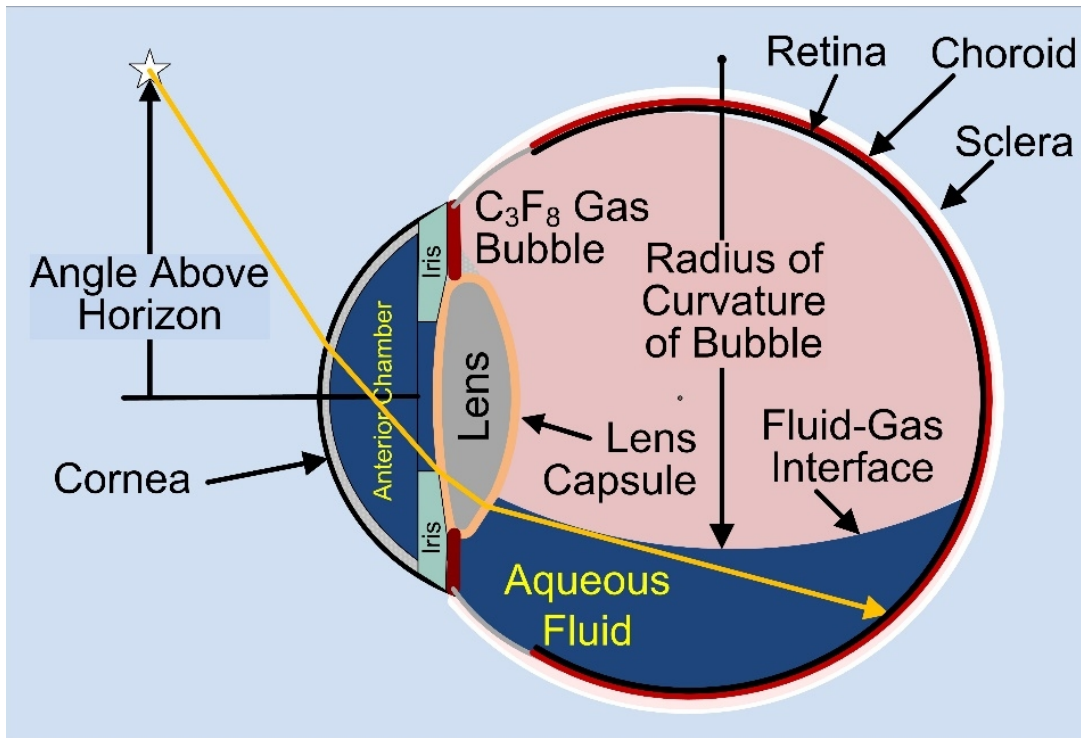


Fig. 2. Schematic drawing of the eye showing the path of the first light that the patient saw after the retinal detachment operations that used perfluoropropane gas. This is a simplified sketch: The angles are not mathematical

Fig. 3, which is unique in the ophthalmology literature, shows my viewpoint of the time sequence of the gas bubble being absorbed and replaced with aqueous fluid. In the first days after the operation, I could only see a dense white fog with shadows and bright areas, like windows. On day 9, I was surprised to see stars in the sky and the surface of the gas bubble. In the next month, I saw many strange reflections off this gas-fluid surface, some were disturbing. This surface looked horizontal, so I measured how far it was above the horizon. On this day, it looked like a straight line about 35 degrees above the horizon. When the gas-fluid surface dropped below the horizon, it stopped being a straight line and started to have curvature, eventually turning into a circle. For example, on day 55 it looked like a circle with a radius of curvature of 25 degrees, whose top was 20 degrees below the horizon. The bottom of Fig. 3 shows quantitative data from my viewpoint of the temporal disappearance of the C_3F_8 bubble. We repeat that Fig. 3 is for one patient, with C_3F_8 gas and in one operation, although after my other two RD operations, the bubble behaved the same way.

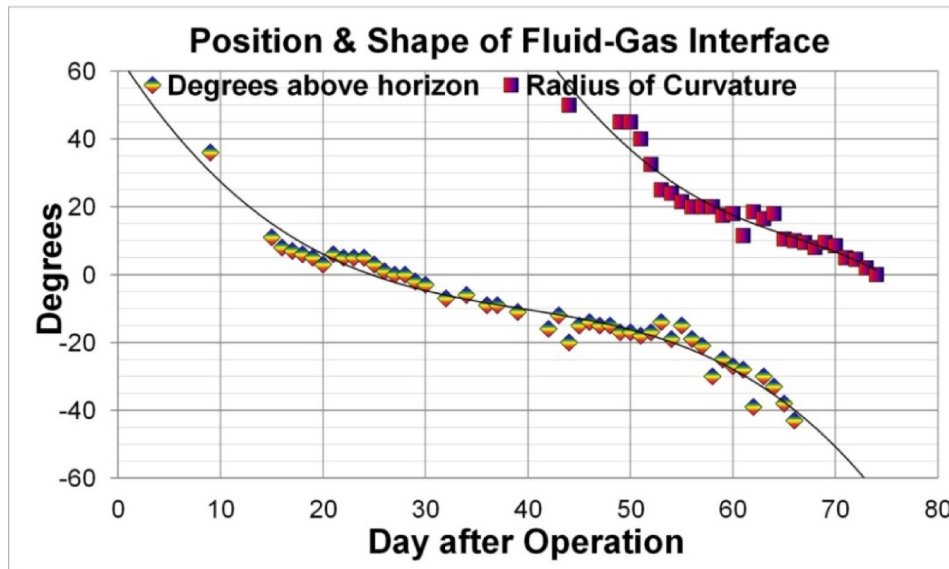
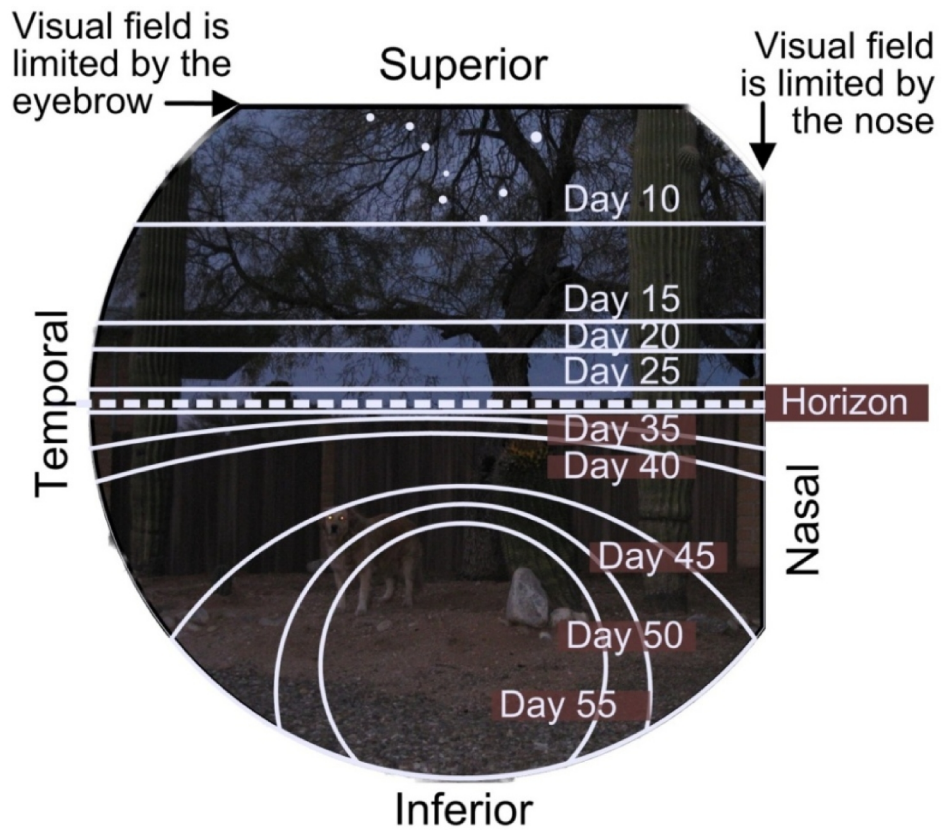


Fig 3. The patient's viewpoint of the time sequence of the gas bubble being absorbed and replaced with aqueous fluid (top). Metrics for the absorption of the bubble (bottom)

In the first few days after an operation, the bubble increases in size, but I could not detect this. I could only see white with shadows and bright objects like windows. Around day 10, I was surprised to see the bottom of the gas bubble. It was in my upper field of view (remember that the lens inverts the image before it is focused on the retina). In Fig. 3, this gas-fluid interface looked horizontal, so I measured how far it was above the horizon. I saw many very strange reflections off this gas-fluid interface. Later at about day 40 the bubble started to look more like a circle and less like a line. So I started measuring the radius of curvature of the bubble. The ophthalmological literature emphasizes the volume of the bubble [4], which may be scientifically more relevant. But as the patient, I did not care about the volume. I only cared about what was happening in my visual field. Fig. 3 is for one patient only, with C_3F_8 gas only and in only one operation, although after the other two RD operations the bubble behaved the same way.

Fig. 3 might not be the first illustration of a patient's view of a disappearing intraocular gas bubble. The abstract of [6] states that the paper contains an analogous description. However, I could not obtain a copy of the paper and it is in French.

2.10 August 3, 2008

Since the implant of the scleral buckle, my eyes were misaligned (strabismus and diplopia) by as much as twenty degrees. On this date I was finally able to align the left and right eye images, albeit with difficulty and not for long. I described this to Ophthalmologist-4, but he offered no advice.

2.11 September 11, 2008, Distorted Vision

The gas bubble from the second retinal detachment operation was finally gone after 10 weeks. The left eye retinal image had become wrinkled, because of the macula-off detachment. The width of the image of the left eye was around $\frac{3}{4}$ the size of the right eye. See Fig. 4. With the left eye, everyone looked like a pinhead, or a person in an El Greco painting. There was some improvement in that the misalignment of the left eye had become smaller and I was able to roughly align the two eyes. Ophthalmologists' have no instruments that could produce a Figure showing as much detail as in Fig. 4. Their closest tool would be an Amsler grid.

2.12 September 12, 2008, Third Bubble

During a routine office visit, Ophthalmologist-4 found a new tear in my retina. He repaired it with 60 pulses of a head mounted laser. He inserted a cryopexy probe on top of the eyeball near the scleral buckle to freeze (cryopexy) the area of the retina above the tear. He removed some fluid from the eyeball and inserted a new bubble of C_3F_8 . But he was doing these procedures while he was seeing other regularly scheduled patients in his office. So he finally gave up and asked me to come back the next day.

2.13 September 13, 2008, Many Laser Pulses

Saturday morning we returned at 8 AM. Ophthalmologist-4 administered 567 laser pulses. He said, "I know you want to ask, why? The answer is bad luck." Over the next few months, there were varying degrees of vertical, horizontal and cyclorotational disparities between the two eyes due to the misdirection (phoria) of the left eye. The pain on the back of eye and the

double vision (diplopia) started with the first surgery on May 12, 2008. However, the diplopia was exacerbated by the cryopexy freezing on September 12, 2008. At this time, with the left eye, everyone looked like Don Quixote, tall and skinny.

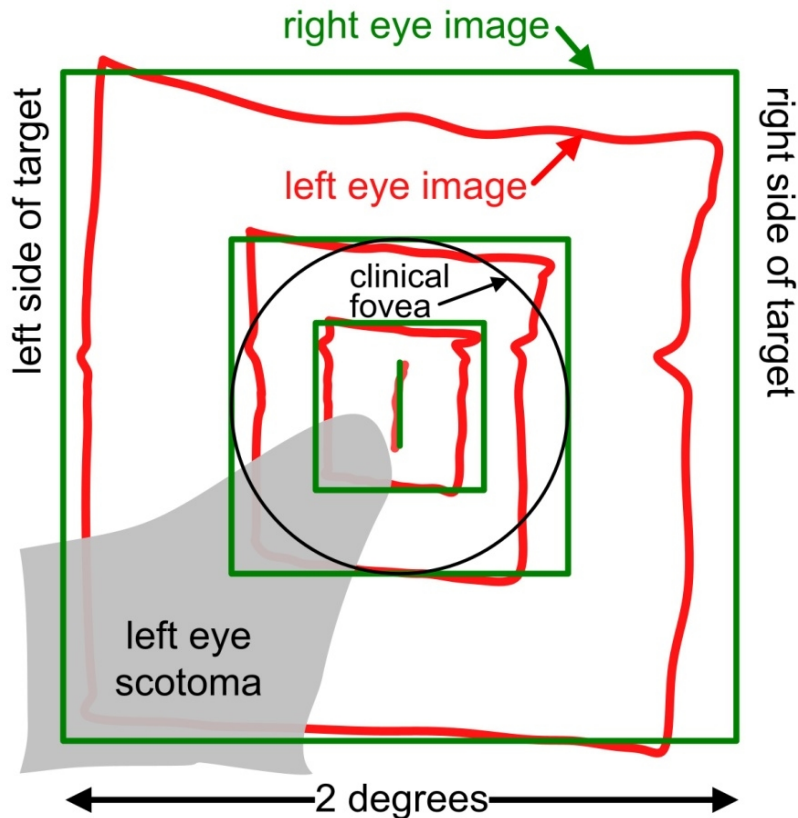


Fig. 4. The patient's viewpoint of binocular viewing of a small black-line target comprised of concentric squares. The right eye's image (green) is the same as the visual target. The left eye's image (red) shows the distortion due to a wrinkled retina or macular pucker. (However, the left eye scotoma did not appear for another year, around October2009.)

At this time, my symptoms were (1) inflammation and pain in the front of the left eye, (2) pain behind the left eye, (3) pain in the brain, (4) double vision, (5) lack of depth perception, (6) poor visual acuity in the left eye due to a wrinkled retina, and (7) poor vision in the *right* eye due to a cataract. Intraocular pressures were always normal.

2.14 October 29, 2008, Macular Edema was Noticed

Using a Heidelberg Engineering OCT instrument, Ophthalmologist-4 saw cystoid edema in the macular area. He also noted that the retina was reattached.

2.15 March 9, 2009, Attempts to Eliminate Edema

The image of the left eye was about $\frac{3}{4}$ the size of the image of the right eye and the left eye's image was wrinkled. Ophthalmologist-4 was prescribing cortical steroids (drops and injections) for five months trying to flatten the macula. There was fluid behind the retina. At various times he called it inflammation, swelling, fluid, a cyst and cystoid macular edema: for the rest of this paper I will refer to this as macular edema. Ophthalmologist-4 noted that the inner limiting membrane (ILM) was not thickened. He injected corticosteroids (Kenalog®) directly into my eyeball. I probably had a reaction to the carrier or the preservative (benzyl alcohol), because the Kenalog turned into white crystals and I was blind in that eye for a week. The intraocular pressure exceeded 30 mm Hg. Thirty-six eye drops per day of three different types (spaced at least ten minutes apart) brought things back to "normal."

2.16 June 1, 2009, the Right Eye

A small inconvenience was caused by the cataract in my right eye. I had intended to have it removed soon after the cataract in the left eye. But when the left retina started falling off, the doctors suggested that nothing be done to the right eye until the left eye stabilized. For about a year, I did not drive my car. Ophthalmologist-5 removed the cataract in the *right* eye and replaced it with a 13 diopter artificial IOL. Although the right eye was his eye, he spent a good deal of time examining and tracking the progress of the left eye.

2.17 July 10, 2009, Additional Intra-ocular Injection

Ophthalmologist-4 injected preservative-free triamcinolone acetonide (generic Kenalog) into the left eyeball. It did not react adversely and it did help with the fluid behind the retina.

2.18 September 4, 2009, Summary of Symptoms

The left eye's image was smaller than the right eye's image, it was wrinkled, it was about eight degrees up, four degrees to the right and was rotated about four degrees clockwise. I had a (possible) aniseikonia headache. I had no depth perception for near objects: therefore, threading a needle, tying a hook on a fishing line or pounding in a nail was difficult, or near impossible.

For about six months, I wore a black patch over my left eye when reading or working on the computer and I wore the black patch on my right eye when I was teaching, riding in a car or watching television. This reduced the pain in the brain. However, Ophthalmologist-4 asked me to stop doing that, because he was afraid the brain would shut down the left eye if I stopped using it. (This is called amblyopia.)

2.19 October 16, 2009, Planning the Seventh Retinal Surgery

At a routine appointment, Ophthalmologist-4 worried about the macular edema and scheduled surgery for October 20. He said that he would go in with his microscope, look, see what is there and try to remove it. He said, "I think this will work."

2.20 October 20, 2009, Peeling the ILM

Ophthalmologist-4 peeled the inner limiting membrane (ILM) over the macula without using dyes. The inner limiting membrane is a diffusion barrier between the vitreous and the ganglion cells of the retina. It is about two microns thick. He removed an area about one mm in diameter. He did this manually, quite a feat! Then he injected Kenalog into the eyeball (fresh hospital Kenalog is preservative free).

Note added in 2013: The purpose of peeling the ILM was to reduce the edema, not to improve visual acuity [7], because visual acuity seldom improves after a macula-off detachment. Peeling of the ILM is used to repair macular holes. However, it has side effects. Tadayoni et al. [8] wrote "ILM peeling may reduce retinal sensitivity, and significantly increase the incidence of microscotomas.... We found that mean retinal sensitivity was significantly lower ... in eyes that underwent peeling than in those that did not. Postoperative microscotomas were also significantly more frequent in eyes that had undergone peeling...." The scotoma that resulted from peeling my ILM is shown in Fig. 4.

2.21 October 21, 2009, Follow-up Exam

The day after the surgery, he said, "That will be your last operation on that eye: that eye can't take any more surgery: it was hard to get the membranes back together." Ophthalmologist-4's practice schedules a patient every ten minutes. Well on that day he said, "They're trying to kill me. Today they have scheduled 89 patients for me."

2.22 November 2, 2009, No Progress

I told Ophthalmologist-4 that peripheral vision in the left eye was good: but the left eye's image was still smaller than the right eye's image. Since the operation, the left eye's image had a two-degree diameter gray-brown cloud over the fovea. He looked and said that it was a hemorrhage and that was not unusual: it will probably go away.

For the last year and a half I have reported to Ophthalmologist-4 that I have had the following symptoms: (1) pain in the front of the left eye, (2) pain behind the left eye, (3) pain in my brain, (4) double vision (diplopia) due to left eye phoria, (5) lack of depth perception (no stereopsis), and (6) poor visual acuity in the left eye due to a wrinkled retina and, since peeling the ILM, a scotoma (an area in the field of vision where the subject sees nothing) in the inferior temporal macula as shown in Fig. 4.

2.23 June 23, 2010, Motrin

I visited Ophthalmologist-4. Vision in the left eye has been about 20/60 to 20/70 for the last half year. I could obtain this only by scanning across the letters and recognizing them with off-foveal vision. However, there was tremendous variability in this measure. Peeling the inner limiting membrane (ILM) over the macula made the vision worse. Ophthalmologist-4 wrote, "Andrew's main problem now is buckle associated discomfort. I am going to put him on a trial of high dose Motrin [sixteen 200 mg pills per day] and consider biofeedback therapy prior to the removal of the scleral buckle." At this time, we lost confidence in Ophthalmologist-4 and switched to Ophthalmologist-6.

2.24 July 27, 2010, New Ophthalmologist

I asked if it would help if we removed the scleral buckle. Ophthalmologist-6 suggested *not* removing the scleral buckle. His optical coherence tomography (OCT) confirmed fluid behind the retina.

At this point my symptoms (and possible known causes) were (1) pain in the front of the left eye and light sensitivity (perhaps caused by the haptics of the artificial lens interfering with the iris), (2) inflammation and intermittent pain behind the left eye (perhaps caused by the scleral buckle or damage to the superior rectus and superior obliquemuscles), (3) pain in the brain {Surely, this had many causes. It could be a continual retinal induced aniseikonia headache (asthenopia). The MRI's did not reveal a cause. A neurologist found no reason for them. They are not migraine or cluster headaches.}, (4) left eye phoria {When looking straight ahead, the left eye's image was rotated about three degrees right, two degrees up and five degrees clockwise. (This may have been caused by the scleral buckle, damage to superior oblique muscle or interference with the inferior rectus muscle.)}, (5) diplopia and lack of stereopsis (caused by the phoria and the wrinkled retina) and (6) poor visual acuity (caused by a wrinkled retina and a scotoma in the inferior temporal macula).

At this time, Optical Coherence Tomography (OCT) images were the cat's meow of ophthalmology. The OCT instrument scans the retina with a laser beam. It stores this information in a computer as a three dimensional model of the eye. The OCT images of my eye showed fluid under the retina, so the doctors tried to get rid of that fluid. That fluid caused an elevated thickness at two places in the retina. They were about five degrees left and right of the fovea. Visual field analysis does not have the resolution to show such defects. In fact, when I looked for evidence of such defects I could not find any. So the OCT images showed a new type of pathology and my ophthalmological treatments over the last two years were directed to reduce these fluids and those potential defects.

At most of my eye exams since May 2007, before dilation, a technician would measure the pupillary reflexes. The right eye was normal; the left eye was irregular and non-reactive (tonic). I presumed that these test results were entered into my records and read by the doctor: but no ophthalmologist ever commented on this anisocoria.

2.25 November 5, 2010, Letter to Ophthalmologist-6

Visual acuity in the left eye is about 20/70. However, viewing a Snellen chart is a primitive indicator of vision. For example, it did not disclose the important additional information that the brain has shut down vision of the left eye by about a log unit. That is, if I want to see a target equally with both eyes in the same illumination, then I must put a neutral density filter in front of the right eye to equalize the perceptual disparity between the eyes. It also failed to disclose retina wrinkles and scotomas as shown in Fig. 4. It did not reveal lack of stereopsis or color vision deficiencies. If I were given enough time and encouragement, I would saccade across the letters of the Snellen chart and recognize the proper letter with off-foveal vision.

2.26 December 3 and 8, 2010, MRIs

Magnetic Resonance Imaging (MRI) of the brain and left eye orbit showed no cause for the pain in the brain. This pain seems to be localized in a cylinder two inches in diameter stretching between the temples.

2.27 December 10, 2010, Diagnosis of Phoria

The optometrist measured the misalignment of the eyes. This was the first time that anyone had measured it. He suggested that the pain in the back of the eye and the vertical, horizontal and cyclorotational disparities between the two eyes were due to the scleral buckle and the effects of the surgery on the superior rectus and perhaps the superior oblique muscles. He prescribed new spectacles with horizontal and vertical prisms for both eyes. These spectacles reduced the pain in the back of the eye and attenuated the pain in the brain. Since the first retina operation, when looking straight ahead (eyes in primary position), my left-eye image was $5.7^{\circ} \pm 1.5^{\circ}$ right, $3.6^{\circ} \pm 2.3^{\circ}$ up and $4.5^{\circ} \pm 1^{\circ}$ clockwise. The optometrist recommended spectacles with horizontal prisms of one Δ (diopter) base-in for both eyes, and two Δ base-down for the OD and two Δ base-up for the OS. A prism diopter, Δ , is about 0.57° . Although it is only the left eye that is misaligned, half of the needed prism correction is put into each spectacle lens. Nothing was done for the left eye exocyclophoria.

Note added in 2013: alternative words that describe my eye position at rest are that the left eye was abducted 5.7° , depressed 3.6° and exocyclorotated 4.5° .

2.28 December 29, 2010, Diagnosis of Tonic Pupil

The optometrist told me that the right eye pupillary response was normal, but the left pupil was dilated, oblong shaped, with the pulling point at 11 o'clock, and was nonresponsive (tonic). The optometrist wanted to run an experiment to see if the origin of the tonic pupil was mechanical or neural. One possible neural cause of the tonic pupil was an injury (during the surgeries) to the axons in the short ciliary nerve between the ciliary ganglion and the ciliary muscles. So he called a retina specialist distantly involved with my case, Ophthalmologist-8. Together they decided that pilocarpine (a pupil constrictor) might help and would not hurt. The pilocarpine did not cause the pupil to constrict; therefore, the tonic pupil was due to mechanical not neural restraints. The pilocarpine was then discontinued. This experiment led us to think that perhaps the haptics were hooked into the iris. However, we did not have an instrument that could image the haptics.

Note added in 2013: This situation led to the lens replacement surgery of July 21, 2011.

2.29 January 24, 2011, Confirmation of Tonic Pupil

Ophthalmologist-7 noted that the left pupil was an oblique oval with a diameter of five mm. Prism cover testing showed five prism diopters.

2.30 January 31, 2011, Summary of Symptoms

I gave the optometrist the following summary of my symptoms: (1) inflammation and pain in the front of the eyeball. I described it as a scratchy, blood-shot irritation of the eyeball. This pain was intermittent. It came on a half-dozen times a day and lasted 10 or 20 minutes. The left eye was light sensitive. After walking the dog in the sun for a half-hour, the eyelid was almost closed and the eye hurt. (2) Pain in the back of the eyeball: an intermittent localized pain, sometimes sharp, sometimes dull. It felt like a foreign body was trapped in the orbit. I attributed it to the scleral buckle or to inflammation around the buckle. This pain had been there for two years. (3) Pain in the brain, a continual periphery-induced aniseikonia headache (asthenopia). My brain hurt when I got up in the morning: it got worse as the day

went on. I had put a black patch on the left eye for close vision like reading on a computer screen and on the right eye for distance vision like when watching TV or being outside. That helped, but Ophthalmologist-4 and the Optometrist asked me to stop doing that, because they were afraid that the brain would shut down that eye. So I put a small (one degree) dot in the center of the left lens. This blocked the distorted left eye image and caused the left eye to use peripheral not foveal vision. I had hoped that this would ameliorate the static aniseikonia. The optometrist's prism spectacles did help with the pain. Roughly, the pain seemed to be localized to a region between the temples. If I rubbed the temples hard, it helped to alleviate the pain. This pain got worse five or ten times a day. These episodes lasted a half hour. However, the MRIs found nothing wrong and my neurologist found nothing wrong. (4) If I bent over to pick up something from the floor, the left eye hurt. About once a day, I would lose my balance and almost fall.

My notes state that Ophthalmologist-7 wrote in his report that all four of these pains were consistent with the eight operations that were done on that eye. He also offered nothing to relieve the pains.

2.31 Spring 2011, Finding a Specialist

Now the biggest difficulty was finding an ophthalmologist who had the experience and instruments to handle this one-in-a-million problem. Finally, Ophthalmologist-5 recommended Ophthalmologist-9, with whom he had done a fellowship, at the UCLA Medical School. Ophthalmologist-9 was a professor of ophthalmology specializing in the anterior chamber (cataracts and refractory surgery).

2.32 May 6, 2011, First visit to Ophthalmologist-9

Ophthalmologist-9 and two of his Fellows spent over an hour examining me. He wrote in his report, "Ocular Motility... With Distance Fixation cc: 6 prism diopter left exotropia and 4 prism diopter left hypertropia, Left incyclotortion persists after horizontal and vertical deviations are neutralized.... The left pupil was 3×4 mm, oval, and peaked at the 11 o'clock position... posterior synechiae [meaning places where the iris adheres to lens] at the superonasal optic-haptic junction... A single posterior synechia is noted at the 11 o'clock position. The iris is stuck to the optic-haptic junction at this location... The quality of the central vision in his left eye is poor. He must scan over letters to read them, and even when he does, his acuity is not very good."

2.33 June 17, 2011, Preoperative Visit

Ophthalmologist-9 noted, "2 permanent sutures that are attached to the scleral buckle tent up, but do not pierce the conjunctiva."

2.34 July 21, 2011, Lens Exchange Operation

Ophthalmologist-9 noted significant posterior synechia superonasally, an eccentric pupil and a chafe between the iris and the square edge of the IOL. He performed refractive cataract surgery with peripheral corneal relaxing incisions. He removed the IOL in the left eye and replaced it with a type of lens that was designed to be placed in the ciliary sulcus (Starr Surgical AQ20110V). In two months the pain in the iris was gone, but the pupil was still noncircular and nonresponsive (tonic).

Ophthalmologist-9's reports were excellent: they were clear, specific and detailed and he made sure that copies were sent to all seven of my previous principal doctors. Evidentially the optometrist and the eight ophthalmologists that had examined me before had never seen this particular cluster of symptoms. So, I was a rare patient. I think that doctors in medical schools are more experienced in dealing with rare cases. So, in retrospect, when I realized that my case was so rare and I found Ophthalmologist-9 at a medical school that solved my major problem, perhaps I should have stayed with him, even though it would have meant frequent trips between Tucson and Los Angeles and a more expensive medical insurance plan.

2.35 January 25, 2012, Revisiting the Pain Behind the Eye

The optometrist noted inflammation of the sclera and of the anterior chamber. He prescribed Bromday and Pred Forte. This prompted Ophthalmologist-6 to inspect the suture securing the scleral buckle.

2.36 May 8, 2012, Ophthalmologist-6 is Optimistic

In his consultation report Ophthalmologist-6 wrote, "Bahill was in again with his remarkable scientific knowledge and his scientific analysis of what is happening in his left eye. ... Summary: The only treatable condition here is the macula edema."

2.37 June 4, 2012, Old Suture Removed

For four years, my sclera was inflamed, blood-shot and it hurt. Bromday seemed to be helping. But on June 4, in an in-office operation, Ophthalmologist-6 removed an exposed Dacron suture in the sclera from the original scleral buckle operation of May 12, 2008. The pain dropped by 40%. But then he noted a 2mm fistula in the conjunctiva over the scleral buckle. He consulted with his associate, Ophthalmologist-10, and then suggested an operation in the hospital.

2.38 July 18, 2012, Fistula Sutured

Ophthalmologist-6 sutured a conjunctiva fistula in the sclera over the scleral buckle. The operation went well, except that the area became infected. Ophthalmologist-6 and Ophthalmologist-10 treated the infection with Ofloxacin and Neo/Poly/Gram.

2.39 November 6, 2012, Large Macular Edema

The optometrist noted that his OCT instrument showed an overall retinal thickening with a maximum thickness near 500 microns in the area centered five degrees temporal of the fovea. The optometrist recommended that I move up my next visit with Ophthalmologist-6 and sent a consultation letter to him.

2.40 November 26, 2012, Treatment of Macular Edema

Ophthalmologist-6's OCT instrument confirmed the measurement of this macular edema with a thickness of 427 microns in the area centered five degrees temporal of the macula. He recommended reapplication of cortical steroids (Durezol) four times a day. Table 2 summarizes the eye drops that I have taken.

2.41 December 27, 2012, Macular Edema

The macular edema had started in 2008. It was detected and measured with OCT scans. It was treated with corticosteroid eye drops Omnipred® and Pred Forte®, injections of Kenalog®, peeling of the inner limiting membrane (ILM) over the macula, and eye drops of Xibrom™, Bromday™, Acular® and finally Durezol® four times a day. Note added in 2014: In Zeiss Cirrus OCT scans performed from 2008 to 2012, in the ILM-RPE Thickness diagram, the thickness of my left eye's retina in a region five degrees temporal of the fovea was $(\bar{x} = 358 \mu\text{m}, \sigma = 86, n = 23)$. We computed similar numbers using B-scans. After using Durezol, in scans performed in 2013 and 2014, the thickness of my retina in this same region was $(\bar{x} = 289 \mu\text{m}, \sigma = 41, n = 7)$. For comparison, the thickness of my right eye retina in this region was $(\bar{x} = 298 \mu\text{m}, \sigma = 1.4, n = 10)$. The left retina was thinner than the right retina because of peeling the ILM. Unfortunately, eliminating the edema did not cure the visual acuity deficit.

Table 2. Over the last six years, ATB has used the following eye drops

Category, purpose	Generic name	Brand name
Corticosteroid, Anti-inflammatory	Difluprednate 0.05%	Durezol® emulsion
	Prednisolone acetate 1%	Omnipred®
	Prednisolone acetate 1%	Pred Forte®
	Triamcinolone acetonide	Kenalog® (by injection)
NSAID, Anti-inflammatory	Bromfenac 0.08%	Xibrom™
	Bromfenac 0.09%	Bromday™
	Ketorolac 0.4%	Acular®
Vasoconstrictor, Antihistamine, Anti-inflammatory	Naphazoline HCl, Pheiramine Maleate	Naphcon A®
	Intra-ocular pressure reduction	
alpha agonist	Brimonidine tartrate 0.15%	Alphagan®
beta-adrenergic blocker	Levobunolol HCl 0.5%	Betagan®
cholinergic agonist	Pilocarpine HCl 1.0%	
Antibiotic	Gatifloxacin 0.3%	Zymar®
	Gatifloxacin 0.5%	Zymaxid™
	Moxifloxacin HCl 0.5%	Vigamox® Solution
	Neo/Poly/Gram	Neosporin®
Artificial Tears and Lubricants	Ofloxacin 0.3%	Ocuflox®
	Propylene glycol	Systane®
HCl means hydrochloride		

2.42 December 29, 2012, More Mysteries

If there were only one object in my visual field and it was a small green dot of light, then it appeared green to my right eye and white to my left eye. This was repeatable in intraocular pressure tests (glaucoma air-puff test, Reichert AT555 non-contact tonometer). I had mentioned these peculiarities for two years, but I did not have experiments to explain them, nor did anyone else.

2.43 March 27, 2013, Color Blindness

The fovea of the left eye is colorblind. When a small visual target is seen with the fovea, the left eye misperceives its color. A green laser dot on a white background appears white or bluish-white. These effects would be consistent with the destruction of ganglion cells [9] during the ILM peeling of the left eye.

Note added in 2014 from [10]. The fovea of the left eye is color vision deficient. When a small (0.07 degree diameter) green dot of laser light was seen with my fovea, it appeared green to the right eye and white to the left eye. This was repeatable initially with intraocular pressure tests and later with lasers in my laboratory.

For the Ishihara color blindness test [11], distance from the screen was adjusted so that each of the test plates was two degrees in diameter. Viewing was monocular. With my right eye, I perceived all 22 of the Ishihara test plates correctly. With my left eye, I perceived none of these test plates correctly.

<http://www.colour-blindness.com/colour-blindness-tests/ishihara-colour-test-plates/>.

For the Hardy-Rand-Rittler (HRR) pseudoisochromatic test, distance from the screen was adjusted so that each of the test plates was two degrees square. Viewing was monocular. With my right eye, I perceived the first seven HRR test plates correctly. With my left eye, I perceived none of these test plates correctly.

For the X-Rite color IQ test (a simplified on-line version of a Farnsworth-Munsell 100 Hue Test), distance from the screen was adjusted so that each of the squares was one degree. Viewing was monocular. My right eye scored 16, which is low and therefore good: my left eye scored $\bar{x} = 200 \sigma = 52 n = 5$, which is poor and in the 99th percentile.

http://xritephoto.com/ph_toolframe.aspx?action=coloriq.

The results of all three of these tests were size dependent. If the targets were five or ten degrees in visual angle, then I performed much better.

A recent realization revealed that peeling the ILM produced both color blindness in some areas of the macula [10] and total blindness in the area of the scotoma shown in Fig. 4!

2.44 October 17, 2013

My intraocular pressures (IOP) were 13mm Hg, as they have been for the last year. With the exception of the incidence with the preservative in Kenalog in March 2009, my IOPs seldom went above 20mm Hg.

3. DISCUSSION

Table 3 summarizes the patient's ocular status when this paper was submitted.

3.1 Quality of Life

Because the images in my two eyes are of different sizes and shapes, it is difficult, error prone and time consuming to read. My ability to read lips is diminished, so my hearing

impediment is exacerbated. The lack of stereopsis (depth perception for objects within 10 feet due to the difference in the images of the two eyes) makes it dangerous to climb stairs or even walk on a sidewalk. I lose my balance daily, but fortunately, I have only fallen few times, once I broke my fibula. This lack of depth perception makes it difficult to tighten a small screw, zip up a jacket, pound in a nail, put a nut on a bolt or twist a wire around a receptacle screw terminal.

Table 3. Summary of ATB's condition in October 2013

Symptom	Cause	Treatment	Present condition 100% is best
OS=the left eye, OD=the right eye, IOL=the intraocular lens, ILM=inner limiting membrane			
Pain on front of OS and light sensitivity	The iris was stuck to the square edge of IOL or to the haptics, thereby immobilizing the iris	Replaced IOL	90%, the pupil is still tonic
Pain behind OS	Scleral buckle, its sutures and damage to or obstruction of the superior rectus and superior oblique muscles	Removed exposed suture & sutured conjunctiva fistula over the scleral buckle	80%, the muscles are still obstructed
Poor visual acuity in OS macula	Wrinkled retina, macular edema	Durezol twice a day is keeping the macular edema down	70%
Different size and shape of eye images and one or two log difference in the luminance threshold of OS and OD	Macula-off retinal detachment, peeling the ILM, subretinal edema and disruption of retinal pigment epithelium	Corticosteroid anti-inflammatory eye drops	10%
At rest, OS image drifts up and to the right of OD image causing double vision.	Obstruction of or interference with the superior rectus and superior oblique extra ocular muscles	Prisms in spectacles	60%
Color deficiency in OS fovea	Peeling the ILM	Ishihara test for color blindness, and Farnsworth-Munsell 100 Hue Test	0%
Poor visual acuity in OS fovea	Macular scotoma due to peeling the ILM	Maybe a macular 10-2 threshold visual fields test could quantify it.	0%
General pain in OS	Inflammation of the sclera	OS is blood shot and it hurts for about 15 minutes a few times a day, a drop of Systane or Refresh helps	60%
Pain in the brain	Different images from the two eyes particularly due to cyclorotation	Headaches, five times a day, 30 minute duration	40%

The pain in my brain varies (on a scale of 0 to 10) from one to four. It spikes about a dozen times a day and these episodes last about ten minutes, but sometimes they last for hours. This pain prevents me from working on a computer for extended periods. Sharp occurrences of pain make it impossible to maintain a continuous long chain of thought. Therefore, writing papers or proposals is difficult.

3.2 The Systems Thinking Approach

For the last six years I have complained that I had pain in my left eye, floaters, pain on front of the eye, light sensitivity, poor visual acuity, inflammation, a blood shot eye, foreign body sensation, pain behind the eye, no vision due to the C_3F_8 bubble, no vision due to the Kenalog injection, strange visual effects due to absorption of C_3F_8 bubble, phoria or double vision, headaches, pain on front of the eye, pain behind the eye, poor visual acuity in the macula, poor visual acuity in the fovea, color deficiency in the fovea, general pain, different luminance thresholds for the two eyes, different primary positions of the two eyes (the left eye image drifted up and to the right causing double vision), lack of depth perception, lack of stereopsis and pain in the brain. I also complained about lack of explanations for expectations, ophthalmological instruments being used differently by different technicians, and physician overload.

I have abridged these complaints into the following symptoms (1) inflammation and pain on the front of OS, (2) pain behind OS, (3) pain in the brain, (4) OS misalignment (phoria), (5) double vision (diplopia), (6) lack of depth perception (no stereopsis), (7) poor visual acuity in OS, (8) OS foveal color blindness, (9) OS light sensitivity and (10) OS non-circular and non-responsive pupil. This sounds like many disassociated symptoms. I am sure that the ophthalmologists felt overwhelmed as they treated one symptom at a time.

These ten symptoms seemed like ten different problems. This is like the parable of a group of blind men describing an elephant: each saw a different aspect. But now we can see the relationships between these problems. We can understand this medical history as a system, instead of ten isolated events. As shown in Fig. 5, it can be seen how treating one symptom affected other symptoms.

For years, I had a dozen doctors and a dozen symptoms: each doctor treated his most familiar symptoms, one at a time. This shows the need for face-to-face communication between the ophthalmologists and optometrists. If we had understood this *system* years ago, my treatment surely would have been different.

Note added in 2014 from [3]: To add to the confusion, there are many techniques for documenting a patient's vision: for example subject-reported measures of vision, the view through an ophthalmoscope, the view through a slit lamp, a photograph of a face, optical coherence tomography (OCT) images, fundus photos, visual field diagrams and Optomap images. These techniques can be compared qualitatively, but differences in the techniques preclude precise superposition of the images. A perfect mapping is impossible, because (among other reasons) the algorithms for transforming three-dimensional (3D) shapes into two-dimensional (2D) images are nonlinear and are different for different techniques.

4. LESSONS LEARNED

4.1 Pain

Medical doctors have difficulty successfully treating pain, even if it is in their realm of study and experience. Pain is hard to diagnose, measure, quantify and treat. However, and most importantly, pain is often an important clue as to what is wrong. If the cause is not visually obvious (either to the naked eye, in photos, CAT scans or MRIs), then often it is not successfully treated. In this particular case, for the last six years most ophthalmologists failed to resolve my complaints about pain.

In fact, Ophthalmologist-6 wrote in his May 8, 2012 consultation report, "Bahill was in again with his remarkable scientific knowledge and his scientific analysis of what is happening in his left eye. He still complains of bi-temporal headaches, which I do not believe are related to his eye disease. If there is any connection, it is purely stress or depression related as a result of his concern for his left eye. ... Summary: The only treatable condition here is the macula edema. Hopefully successful treatment will improve the acuity and bring him back to where he was." However, on June 4, in an in-office operation, Ophthalmologist-6 removed an exposed Dacron suture in the sclera from the original scleral buckle operation. The pain that had bedeviled me for seven years dropped by 40%. On July 18, in an in-hospital operation, he sutured a conjunctiva fistula in the sclera over the scleral buckle. The pain dropped by 20%. In summary, in May he said that the only improvement that could be made was reducing the macular edema: but in June and July, he performed operations that substantially reduced the pain. It is hard to predict pain resolution.

Before each of my operations, the ophthalmologist discussed likely outcomes and some risks of the operation. However, none of them mentioned potential postoperative pain. We believe that the ophthalmologist should know about the types of pain that could result from each type of ocular surgery. Perhaps they could describe in a brochure or a computer animation what the pain could be like. They could tell the patient what to do if such pain occurs. And then they could explain what they would do in response to alleviate that pain and correct the operation. However, this would all require uncompensated time.

4.2 Communications

From this case, we have learned a little bit about the medical profession. I was not simply jumping around trying to find a doctor that could cure my problems. Instead, most of these doctors were working together to help me. Certainly, they exchanged referral reports. One pair talked on the telephone, and another pair talked in person about this case. Perhaps it would have been better if there were more face-to-face communications, but that would have required extra time, money and resources.

Most of their communications were implemented by FAX, which makes transmission of high-resolution images impossible. Their referral reports varied in quality: some were incomprehensible because the doctor used a canned report generation program, some were superficial, some were merely boilerplate, but the reports of one doctor were truly excellent. This means that we have examples of excellence. It is important that the patient and the doctors ensure that all relevant parties (including the patient, when appropriate) get copies of the reports. In my experiences, most of the time this link failed.

Often referral reports were written by inclusion of standard common phrases. Sometimes they started with partially filled out forms with default values checked. Two of my doctors' reports stated that I had passed the Ishihara color blindness test, but actually, they did not administer this test. However, abandoning such forms and short cuts would cost time.

4.3 Selecting a Doctor

I have found that searching the Internet and asking friends for recommendations about good ophthalmologists was not useful. People tend to make recommendations based on only a few data points. Searching the Internet to find specific procedures that I wanted the doctors to use was futile. My best results came from asking doctors that I trusted for referrals and then trusting the judgments of these doctors [although this process was also fallible]. In the future, I will ask what the ophthalmologist's patient load is. I will not recommend ophthalmologists who schedule more than six patients per hour nor the cataract surgeons who schedule more than four operations per hour. The average ophthalmologist can perform a cataract surgery in less than ten minutes. However, scheduling patients at this rate would not allow for bathroom breaks, time to fix minor complications, time to change equipment or time to switch IOLs.

An anonymous reviewer of this paper wrote, "A retina surgeon seeing 6 patients per hour is the norm and most in private practice see up to 10 per hour. That's the reality of being a small businessman.... Likewise face-to-face communication for each patient is impossible with physicians seeing 500+ patients per week and none in the same location."

In the last six years, I have had 12 eye operations and 150 doctor's visits. I estimate that, on average, (a) the ophthalmologists scheduled a patient every 20 minutes with a standard deviation (SD) of 10 and a range of 10 to 60, (b) on each visit, the ophthalmologists and/or their staff spent 30 minutes with me with a SD of 15 and a range of 10 to 90, (c) Each operation lasted 65 minutes with a SD of 15 and a range of 30 to 90.

4.4 Invisible Gorilla

When people focus on a task that demands their attention, they usually fail to notice unexpected objects and events that occur in full view. This phenomenon is known as inattention blindness, because people typically do not consciously perceive aspects of their world that fall outside of the focus of their attention [12]. Medical doctors are just like the rest of us: they suffer from inattention blindness; they only see what they expect to see.

From the very first surgery until today, I have complained about pain in the eye. In retrospect, it seems that initially the pain was caused by the iris being trapped by the edge of the original IOL: but it was difficult to discover this, because people do not see what they do not expect to see.

On December 29, 2010, the optometrist gave me a through exam lasting 1.5 hours. He looked for unusual things. Finally, he told me that the right-eye pupillary response was normal, but the left pupil was dilated, oblong-shaped with the pulling point at 11 o'clock, and was nonresponsive (tonic). This was the needed breakthrough. He had looked at the iris, which no one else had done.

Ophthalmologist-1 was looking for evidence of the success of his surgery; therefore, he only looked at visual acuity: he did not look at the iris. Ophthalmologist-3 was using his slit lamp to look for inflammation; therefore, he did not look at the iris. Ophthalmologist-4 was trained to look at the retina; so he did not look at the iris. Ophthalmologist-5 was trained to look at the lens; so he did not look at the iris. Ophthalmologist-6 was trained to look at the retina; so he did not look at the iris. Ophthalmologist-7 was a neuro-ophthalmologist trained to look for neurological problems: he noted the tonic pupil, but said nothing about it.

At the beginning of each exam, a technician measured intraocular pressures, Snellen acuity and pupillary reflexes. The ophthalmologists often commented about the pressures and the acuity, but none mentioned the abnormal pupil.

It would be prohibitively expensive for each ophthalmologist to look at all measurements that were taken, read all of the information presented by the patient, and examine all aspects of the eye. Each ophthalmologist focuses on his or her specialty and leaves tangents for others to follow up.

4.5 Process

In complicated procedures involving many physicians and many physical systems, it can be unclear who is in charge of the overall system. The one in charge might not be a physician; it might be insurance or hospital rules. For example, some hospital rules require physicians to “work on only one body part at a time.” In addition, there is usually no patient’s advocate, who knows the system and is particularly interested in only the patients’ best interests. Perhaps both of these roles are played by the patient or a member of the patient’s family.

For every visit, the patient should have a written letter listing symptoms and questions to ask the doctor. It is the patient’s responsibility to make sure that the doctor reads the letter. Often he/she did not. Also, I guess that it is the patient’s responsibility to make sure that tests and measurements (such as intraocular pressure, visual acuity and pupil reflexes) made by technicians are read by the doctor, because the process does not. Finally, the patient should bring several copies of consultation reports, one should be given to the receptionist to be scanned into the patient record and another should be given directly to the doctor. The process does not ensure that the doctor reads consultations.

The medical profession does not seem to have a strong culture of using feedback from patients and other physicians: often they do not even checkup on their own work. For example, ophthalmologist-1 never looked for possible complications of his cataract surgery such as a trapped iris, cystoid macular edema, intraocular infection or signs of potential retinal detachment. He never viewed the haplets of the IOL that he implanted: we do not know if he even had instruments for doing so. Ophthalmologist-4 did not look for possible complications of retina surgery such as strabismus, diplopia or pain and he did not look for possible complications of peeling the inner limiting membrane such as central scotomas.

It seems that the goal of the present process is to deliver the most cost-effective medical treatment, requiring the least amount of physician time, to the largest number of patients. Other goals must be the responsibility of the patient.

4.6 Miscellaneous

Be sure to shake eye drops before use, because some are suspensions, not solutions or emulsions. In suspensions, the solids will eventually fall to the bottom. Try to use preservative free eye drops.

Professors in medical schools are probably more experienced in dealing with rare cases. When I realized that my case was rare and I found an ophthalmologist at a medical school that solved my major problem, maybe I should have stayed with him, even though it would have meant frequent trips between Los Angeles and Tucson.

My final advice is, do not accept an appointment for surgery right before the surgeon is scheduled for vacation, like I did twice! If you do, the surgeon may be distracted and you will miss follow-up care with the person who did your surgery.

5. CONCLUSION

(1) Pain is hard to diagnose, measure, quantify and treat, making it frustrating for both the patient and the physician: in my case, there were many causes of pain and this produced confusion. (2) Face-to-face communication between the dozen involved doctors did not exist: furthermore, many times the written communications were not received, read or understood. (3) In complicated procedures involving many physicians, perhaps there should be a patient's advocate, who knows the system and who's only concern is the patient. (4) I found the best metric for choosing a doctor was the amount of time that he or she scheduled for each appointment or operation. (5) For the last six years, I complained about ten specific symptoms, which were treated individually: treating this case as a system of interacting problems led to a better understanding and resolution.

CONSENT

The patient (the first author) has given his informed consent for this report to be published.

ETHICAL APPROVAL

All authors hereby declare that all experiments have been examined and approved by the appropriate ethics committee and have therefore been performed in accordance with the ethical standards laid down in the 1964 Declaration of Helsinki.

ACKNOWLEDGEMENTS

For helpful comments on the manuscript, we thank members of the Systems Engineering Brain Trust: Bruce Gissing, George Dolan, Jerrold Swain, Bob Sklar and Brad Sowers. We thank Lawrence Jones Esq. for legal advice.

COMPETING INTERESTS

The authors have declared that no competing interests exist.

REFERENCES

1. Stark L, Bahill AT, Ciuffreda KJ, Kenyon RV, Phillips S. Neuro-optometry: An evolving specialty clinic. *American Journal of Optometry and Physiological Optics*. 1977;54:85-96.
2. Jones WL (editor). *Optometric clinical practice guideline care of the patient with retinal detachment and related peripheral vitreoretinal disease reference guide for clinicians*, American Optometric Association, St. Louis, MO; 2004.
3. Bahill AT, Barry PJ. Multimodal views of the human retina, *Ophthalmology Research: An International Journal*. 2014;2(3):121-136.
4. Bahill AT. Model for absorption of intraocular gas after retina surgeries, submitted for publication; 2014.
5. Hartmann GC. Physical model for absorption of intraocular gas. *Digital Journal of Ophthalmology*. 2013;19(2). DOI: 10.5693/djo.01.2013.01.002.
6. Bertin S, Chauvaud D. Simple retinal detachment: Computer reconstruction of visual perception during the first month after surgery. *J Fr Ophtalmology*. 2000;23(10):1026-1028.
7. Nadal J, Verdager P, Canut MI. Treatment of retinal detachment secondary to macular hole in high myopia: Vitrectomy with dissection of the inner limiting membrane to the edge of the staphyloma and long-term tamponade. *Retina*. 2012;32(8):1525-1530.
8. Tadayoni R, Svorenova I, Erginay A, Gaudric A, Massin P. Decreased retinal sensitivity after internal limiting membrane peeling for macular hole surgery. *British J Ophthalmology*. 2012;0:1-4. Doi:10.1136/bjophthalmol-2012-302035.
9. Kolb H, Nelson R, Fernandez E, Jones BW (editors). *Webvision: The Organization of the Retina and Visual System*. Available: <http://webvision.med.utah.edu/book/>. Accessed May 25, 2014.
10. Bahill AT. A new test for acquired color blindness, under review for publication; 2014.
11. Flück D. Colblindor. Available: <http://www.colblindor.com/color-arrangement-test/>. Accessed May 25, 2014.
12. Chabris C, Simons D. *The Invisible Gorilla: And Other Ways our Intuitions Deceive us*, New York, Crown Publishers, 2010. Available at: <http://www.theinvisiblegorilla.com/videos.html>. Accessed May 25, 2014.
13. Lee RM, Foot B, Eke T. Posterior capsule rupture rate with aknetic and kinetic block anesthetic techniques. *J Cataract Refract Surg*. 2013;39(1):128-31. Doi: 10.1016/j.jcrs.2012.11.002.
14. Haug S, Bhisitkul RB. Risk factors for retinal detachment following cataract surgery. *Current Opinion in Ophthalmology*. 2012;23(1):7-11.
15. Clark A, Morlet N, Ng JQ, Preen DB, Semmens JB. Risk for retinal detachment after phacoemulsification: A whole-population study of cataract surgery outcomes. *Arch Ophthalmology*. 2012;130(7):882-888.
16. Benson SE, Schlottmann PG, Bunce C, Xing W, Charteris DG. Optical coherence tomography analysis of the macula after scleral buckle surgery for retinal detachment, *Ophthalmology*. 2007;114:108-112.
17. Beutel J, Dahmen G, Ziegler A, Hoerauf H. Internal limiting membrane peeling with indocyanine green or trypan blue in macular hole surgery a randomized trial, *Arch Ophthalmology*. 2007;125(3):326-332. Doi:10.1001/archopht.125.3.326.

APPENDIX: SUCCESS RATE

What is the likelihood of success for a medical procedure? That is a hard question to answer, because it depends on the type of operation, the patient, the surgeon, the staff, the year, the operating equipment and the definition of success. This appendix examines published success rate examples for cataract and retinal detachment operations. The percentages do not total to 100% because the studies had different definitions for the outcomes, which were not mutually exclusive. There is a lot of variability in these numbers as is demonstrated by the large standard deviations.

A.1 Cataract Surgery Success Rate

For simplicity, let us define cataract surgery success as an operation where the biological lens was removed and an artificial IOL was inserted without serious complications. With this definition, papers published in the last decade have documented that 97% of cataract

operations were successful ($\bar{x} = 96.7, \sigma = 3.6, n = 11$) the numbers in parenthesis are (average, standard deviation and number of published papers used for the analysis), while 0.8% had posterior capsule rupture [13], 1.4% caused cystoid macular edema that produced visual acuity less than 20/40 ($\bar{x} = 1.4, \sigma = 0.6, n = 8$), 0.7% caused intraocular infection ($\bar{x} = 0.7, \sigma = 0.4, n = 11$), which is called endophthalmitis, and 1% were followed by retinal detachment within a year [14] and [15]. The percentages do not total to 100% because the outcomes are not mutually exclusive.

A.2 Retinal Detachment Surgery Success Rate

Of retinal detachment surgeries, about 90% were successfully repaired with a single operation. In the remaining cases, the retina detached again and needed another operation that had a 50% success rate, which yields an overall success rate of 95%

http://www.betterhealth.vic.gov.au/bhcv2/bhcarticles.nsf/pages/Retinal_detachment.

If the retina was successfully reattached, another possible failure was ocular misalignment after surgery. In one study, of the 821 patients who underwent scleral buckle surgery 1.5% developed strabismus and diplopia

<http://www.ncbi.nlm.nih.gov/pubmed/17978674>.

Another study reported that of the 1030 patients who underwent scleral buckle surgery 3.8% developed strabismus and diplopia

<http://www.ncbi.nlm.nih.gov/pubmed/22466475>.

A third study reported that of the 750 patients who underwent scleral buckle surgery 3.3% developed strabismus and diplopia

<http://80.36.73.149/almacen/medicina/ofthalmologia/enciclopedias/duane/pages/v6/v6c059.html>.

Summarizing the data in these three review papers, we find that of twenty eight hundred patients who underwent scleral buckle surgery three percent had postoperative ocular misalignment ($\bar{x} = 2.9, \sigma = 1.2, n = 3$).

Another possible failure mode was macular edema. One paper [16] stated that 55% of their patients who had scleral buckles implanted had cystoid macular edema a. k. a. sub retinal fluid ($\bar{x} = 42, \sigma = 37, n = 9$). Less than 1% of retinal detachment operations produced intraocular infection ($\bar{x} = 0.7, \sigma = 0.4, n = 11$).

A.3 Interlimiting Membrane Peeling Success Rate

Macular holes in the retina are commonly treated by peeling off the innerlimiting membrane. This operation is effective in closing macular holes. However, ILM peeling has complications: 39% caused central scotomas [17 et al.] ($\bar{x} = 39, \sigma = 15, n = 5$), 0.1% resulted with infection, 1% produced retinal detachment and 75% created a need for cataract removal within one year. It is not known how often ILM peeling produced color blindness in the fovea [10].

BIOGRAPHICAL SKETCHES

Terry Bahill is an Emeritus Professor of Systems Engineering and of Biomedical Engineering at the University of Arizona in Tucson. He received his Ph.D. in electrical engineering and computer science from the University of California, Berkeley, in 1975. He is the author of six engineering books and over two hundred and fifty papers, over one hundred of them in peer-reviewed scientific journals. Bahill has worked with a score of technical companies presenting seminars on Systems Engineering, working on system development teams and helping them to describe their Systems Engineering processes. He holds a U.S. patent for the Bat Chooser, a system that computes the Ideal Bat Weight for individual baseball and softball batters. He was elected to the Omega Alpha Association: the Systems Engineering Honor Society. He received the Sandia National Laboratories Gold President's Quality Award. He is a Fellow of the Institute of Electrical and Electronics Engineers (IEEE), of Raytheon Missile Systems, of the International Council on Systems Engineering (INCOSE) and of the American Association for the Advancement of Science (AAAS). He is the Founding Chair Emeritus of the INCOSE Fellows Selection Committee. His picture is in the Baseball Hall of Fame's exhibition "Baseball as America." You can view this picture at <http://www.sie.arizona.edu/sysengr/>.

Patrick J. Barry earned his BS at Siena College in Loudenville, NY, with a major in biology and a minor in chemistry. He earned a Doctor of Optometry Degree from the Pennsylvania College of Optometry in 1977 and has been in private practice since 1989, providing primary care Optometric services to the Tucson community. Dr. Barry is a member of the American Optometric Association, the Arizona Optometric Association and the Southern Arizona Optometric Society. He is a Past- President of both the Southern Arizona Optometric Society and the Arizona Optometric Association, where he received the prestigious Optometrist of the Year Award for his dedication to the Optometric profession.
envisioneyecarecenter@gmail.com

© 2014 Bahill and Barry; This is an Open Access article distributed under the terms of the Creative Commons Attribution License (<http://creativecommons.org/licenses/by/3.0>), which permits unrestricted use, distribution, and reproduction in any medium, provided the original work is properly cited.

Peer-review history:

The peer review history for this paper can be accessed here:
<http://www.sciencedomain.org/review-history.php?iid=523&id=23&aid=4811>