

Safety and Efficacy of Oral Itraconazole versus Combination with Oral Isotretinoin in Superficial Dermatophytosis: A Randomised Clinical Trial

DIVYA PRIYADARSHI¹, DEEPIKA AGARWAL², ANKUR TALWAR³

ABSTRACT

Introduction: Dermatophytes are the most common skin infections mainly treated with itraconazole. However, the persistent nature of the disease has emerged as the major concern over the last few years. Oral isotretinoin, a keratolytic drug is also used along with itraconazole in the management of dermatophytosis.

Aim: To evaluate safety and efficacy of oral itraconazole versus combination with oral isotretinoin in the treatment and recurrence prevention of superficial dermatophytosis.

Materials and Methods: The randomised clinical trial was conducted in the Dermatology Outpatient Department (OPD) of Hind Institute of Medical Sciences, Barabanki district of Uttar Pradesh over 12 months period. A total of 180 adult patients clinically diagnosed with superficial dermatophytosis were recruited and randomised into group A and B. Patients in group A were treated with oral itraconazole 200 mg daily and patients allotted in group B received oral itraconazole 200 mg plus oral isotretinoin 20 mg daily. Both groups were evaluated after every 15 days for two months and followed-up for next two months to assess relapse rate. Treatment efficacy was assessed

by potassium hydroxide (KOH) test done on skin scrapings, erythema score, scaling score and 5D pruritus scale and safety by evaluating for adverse reactions noticed at each sequential visit during study period of two months. The data were analysed by using Chi-square tests and unpaired t-tests and Statistical Package for the Social Sciences (SPSS) software version 26.0. A p-value <0.05 was taken as significant.

Results: Out of 180 patients enrolled, 162 patients (83 in group A and 79 in group B) completed the trial. The patients in group B had early and complete mycological cure, seen in 77/79 (97.5%) patients as compared with 74/83 (89.2%) group A patients (p=0.06) with significantly low recurrence rate (p=0.01). At each follow-up, both groups were assessed on the clinical signs of erythema and scaling rated on 4 points scale (0, 1, 2, 3) and clinical symptom of itching on 5D pruritus scale ranging from 5-25. There was statistically significant difference in the treatment response between studied groups (p<0.05). Hepatic derangements were the most common adverse effects observed in both groups.

Conclusion: Oral isotretinoin can be an effective add on therapy in superficial dermatophytosis management as it induces early remission with significantly less recurrence rate.

Keywords: Dermatophytes, Potassium hydroxide, 5D Pruritus scale

INTRODUCTION

Dermatophytosis is one of the commonest skin infections with a prevalence rate ranging from 36.6-78.4% [1]. The chronic nature of the disease could be due to complex interactions of host, pathogen, environmental, pharmacological and other cofactors [2]. Similarly, the world is also experiencing a hike in the magnitude of chronic, recurrent and atypical dermatophytosis, affecting 20-25% world population, caused by keratinophilic filamentous fungi called dermatophytes belonging to 3 genera: *Trichophyton*, *Microsporum* and *Epidermophyton* [3]. The mainstay of treatment is the topical and systemic antifungals [1]. In today's scenario, topical antifungals have limited role in adults while systemic antifungals like griseofulvin, fluconazole, ketoconazole and terbinafine are associated with low cure rates, more side-effects, various drug interactions and emergence of antifungal resistance in various parts of the country [4-6].

On the other hand, newer antifungals like itraconazole although earlier had high cure rates are now no longer providing a satisfactory clinical cure [7,8]. To overcome this, various regimens not proven so far have been tried, like prolonging treatment duration, increasing standard dose of antifungals, combining more than one antifungals and application of penetration enhancers [9-11]. Few studies proposed that isotretinoin being keratolytic, increases exfoliation of epidermis resulting in shedding of the stratum corneum, thereby decreasing burden of fungal colonies and hence can have synergistic action with itraconazole in superficial dermatophytosis [2,12,13].

In an attempt to overcome the challenges faced by the dermatologists with antifungals, the study was planned to assess whether addition of oral isotretinoin has an edge over itraconazole monotherapy in treatment and prevention of relapses in superficial dermatophytosis. Itching is an individualised parameter difficult to assess since based on various dimensions and hence, 5D pruritus scale was designed to assess treatment response to an intervention in clinical trials. A 5D pruritus scale is easy to apply, consistent and able to determine changes in itching with time in patients with skin diseases [14]. As far as ascertained, no research studies have earlier used 5D pruritus scale as an evaluating parameter to assess clinical response in follow-up visits [14].

Hence, the study was designed to assess safety and efficacy of oral itraconazole versus combination with oral isotretinoin in superficial dermatophytosis. The primary measures were the clinical improvement or resolution of skin lesions assessed by erythema scale, scaling scale and 5D pruritus scale and negative microscopic examination done by KOH test. Secondary measures were examining skin and systemic organs for any adverse effects assessed by laboratory investigations.

MATERIALS AND METHODS

The study was a hospital-based, open-labeled randomised clinical trial conducted on 180 adult participants clinically diagnosed with KOH positive superficial dermatophytosis attending Dermatology OPD of Hind Institute of Medical Sciences, Safedabad, Barabanki district of Uttar Pradesh, India, over 12 months, starting from November

2021 to November 2022 after approval from the Institutional Ethics Committee (IEC Number HIMS/IRB/2021-22/3948).

Inclusion criteria: Superficial dermatophytosis is defined as fungal infection affecting the keratinised layer of epidermis of skin, hairs and nails [1,3]. All skin lesions having itching, erythema, scaling with advancing border was included in the study. Patients aged 18-60 years with tinea corporis and/or tinea cruris and faciei or manuum and pedis with positive KOH test, 20-50% involvement of Body Surface Area (BSA), duration of infection ≥ 3 months, no prior intake of oral antifungal therapy in last three months and no prior topical antifungal application in last one month were recruited.

Exclusion criteria: Patients with chronic hepatic, renal, cardiac or neurological diseases, patients with dyslipidaemia, immunosuppressed patients, pregnant and breastfeeding women and women aspiring pregnancy during or three months after the study period were excluded from the study.

Sample size calculation: Sample size estimation was based on previous study conducted by Kanishk UK [15];

$$n = (Z_{1-\alpha/2} + Z_{1-\beta})^2 \times p_1(1-p_1) + p_2(1-p_2) / (p_1 - p_2)^2$$

Where,

$Z_{\alpha/2}$ = The critical value of the normal distributions at α level of significance (for confidence level of 95%, α is 0.05 and the critical value is 1.96)

Z_{β} = The critical value of normal distribution at β (for a power of 80%, β is 0.2 and the critical value is 0.84)

p_1 and p_2 are the sample proportions of the two groups:

$$Z_{1-\alpha/2} = 1.96 \text{ at } \alpha = 5\% = 0.05$$

$$Z_{1-\beta} = 0.84 \text{ at } 80\% \text{ of power:}$$

$$p_1 = 0.91$$

$$p_2 = 0.74$$

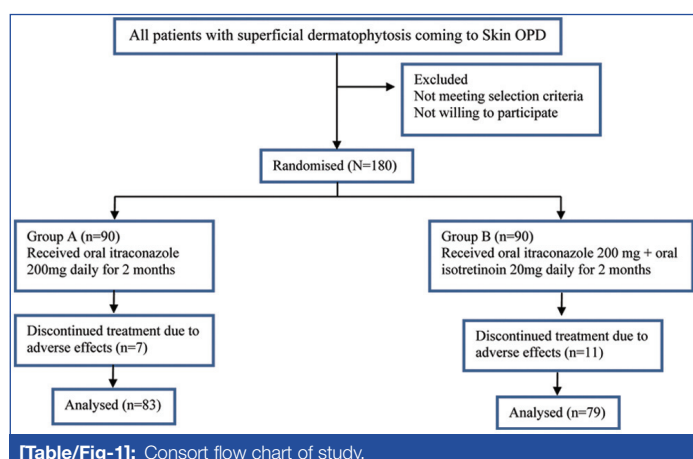
$$n = (1.96 + 0.84)^2 \times \{0.91(1-0.91) + 0.74(1-0.74)\} / (0.91 - 0.74)^2$$

$$n = 74 \text{ in each group}$$

Therefore, 148 total sample size:

Considering 20% dropout of study participants i.e., 29

Sample size was 177~180 (round off). The consort flow chart of study is shown in [Table/Fig-1].



[Table/Fig-1]: Consort flow chart of study.

Procedure: After obtaining informed consent from all participants a detailed history was recorded which included age, gender, occupation, duration and distribution of infection, oral antifungal treatment taken previously (like griseofulvin, fluconazole, ketoconazole, terbinafine, itraconazole) and its duration and other co-existing co-morbidities. The BSA involvement was calculated by "Rule of hand" in each patient [16]. The worst affected dermatophytic lesion was chosen as target lesion. Skin scrapings from the peripheral margin of target lesion was taken with 10 number scalpel blade and collected on a clean glass slide. One drop of 20% KOH was added and cover slip placed and the

specimen was visualised under low power (10 \times) light microscopy by independent observer to visualise fungal hyphae.

Simple randomisation was done by odd and even number and enrolled patients were assigned to either group A (oral itraconazole 200 mg daily) or group B (combination of oral itraconazole 200 mg plus oral isotretinoin 20 mg daily). No topical antifungal treatment was advised but oral antihistamines (levocetirizine hydrochloride 5mg) was given to control the itching if required. All enrolled patients were investigated for Liver Function Test (LFT), Renal Function Test (RFT), fasting lipid profile, Fasting Blood Sugar (FBS), urine pregnancy test and Complete Blood Count (CBC) at baseline. Photographic documentation by digital camera (Samsung Galaxy Note 10+) was done at baseline and at 2nd month by independent observer.

Severity of infection over target lesion in both groups was assessed by chief investigator on basis of pruritus, erythema and scaling at baseline. Erythema and scaling were rated on 4 points scale ranging from 0-3 where 0-absent, 1-mild, 2-moderate, 3-severe [13]. Pruritus was rated on 5D pruritus scale having five domains, namely duration, degree, direction, disability and distribution and ranged from 5 (no pruritus) to 25 (most severe pruritus) [14].

The patients were followed-up every 15 days for next two months with LFT and fasting lipid profile and treatment response was assessed by KOH microscopy, 5D pruritus scale, erythema and scaling score at each sequential visit. Both groups were assessed on clinico-demographic factors which included age, gender, occupation, BSA involvement, duration and distribution of infection. At each follow-up visit, a clinical assessment was made and recorded by chief investigator depending on KOH microscopy, pruritus, erythema and scaling score. A negative KOH microscopy was considered as a mycological cure and absent of erythema, scaling and pruritus score were taken as clinical cure. Both mycological and clinical cure were taken as complete cure [13]. The participants of both groups with complete cure were followed-up for another two months to look for relapse. A positive KOH microscopy or reappearance of erythema, scaling or pruritus parameters were taken as relapse of disease [13]. Participants' compliance with treatment was checked by collection of empty drug wrapper and tolerability was assessed by looking for various adverse effects like skin dryness, lip cheilitis, photosensitivity, hepatic or lipid derangements or gastritis at each follow-up visits.

STATISTICAL ANALYSIS

Discrete variables were presented as frequency counts and percentages, whereas continuous variables were expressed in mean \pm Standard Deviation (SD). Unpaired t-test was used to compare continuous variables, whereas Chi-square test was used to compare nominal variables between the two groups. The p-value < 0.05 was considered significant. Statistical analysis was done using SPSS software 26 version.

RESULTS

A total of 180 participants were included in the study. Among them, 88 (48.9%) were females and 92 (51.1%) were males. The mean age of study participants was 35.8 \pm 11.5 years. Tinea corporis and cruris (24.4%) was present in majority of participants followed by tinea corporis (22.8%) and tinea cruris (21.7%). Both groups were comparable in clinical and demographic characteristics as shown in [Table/Fig-2].

Postintervention KOH microscopic findings between two groups are summarised in [Table/Fig-3]. Mycological clearance was achieved in 74/83 (89.2%) patients in group A and 77/79 (97.5%) patients in group B at day 60 with p-value=0.067 signifying that both treatments were statistically comparable in attaining mycological clearance on day 60. Further on, p-value < 0.05 on day 30 and day 45 signified that group B participants had attained early mycological cure.

Characteristics	Group A n (%)	Group B n (%)	Statistical Significance
Age (years)			
Mean±SD	35.35±11.27	34.04±10.02	t-test=0.82 p=0.41
Gender			
Female	46 (51.1)	42 (46.7)	$\chi^2=0.36$ p=0.55
Male	44 (48.9)	48 (53.3)	
Occupation			
Skilled work	22 (24.4)	24 (26.7)	$\chi^2=0.12$ p=0.73
Unskilled work	68 (75.6)	66 (73.3)	
Duration in days			
Mean±SD	102.3±79.9	116.8±88.39	t test=1.15 p=0.25
Distribution			
Tinea corporis et cruris	19 (21.1)	25 (27.8)	$\chi^2=1.61$ p=0.81
Tinea corporis	20 (22.2)	21 (23.3)	
Tinea cruris	21 (23.3)	18 (20)	
Tinea corporis et cruris et faciei	13 (14.4)	13 (14.4)	
Tinea corporis et cruris et faciei et manuum et pedis	17 (18.9)	13 (14.4)	
Body surface area			
Mean±SD	32.4±8.2	31.9±6.9	t-test=0.44 p=0.66

[Table/Fig-2]: Comparison of clinical and demographic characteristics.

KOH Microscopy	Group A n (%)	Group B n (%)	Chi-square	p-value
Day 0				
Positive	90 (100)	90 (100)		
Day 15				
Negative	6 (6.7)	3 (3.3)	0.83	0.36
Positive	84 (93.3)	86 (95.6)		
Discontinued treatment	0	1 (1.1)		
Day 30				
Negative	60 (66.7)	73 (81.1)	5.09	0.024
Positive	28 (31.1)	13 (14.4)		
Discontinued treatment	2 (2.2)	4 (4.4)		
Day 45				
Negative	69 (76.7)	78 (86.7)	5.16	0.023
Positive	18 (20.0)	6 (6.7)		
Discontinued treatment	3 (3.3)	6 (6.7)		
Day 60				
Negative	74 (82.2)	77 (85.6)	3.35	0.067
Positive	9 (10.0)	2 (2.2)		
Discontinued treatment	7 (7.8)	11 (12.2)		

[Table/Fig-3]: Comparison of KOH microscopy.

The mean 5D pruritus scale for group A and B was comparable on day 0 of the intervention (p-value=0.17). During follow-up visits, there was gradual reduction in 5D pruritus scale in both groups as shown in [Table/Fig-4]. However, there was greater reduction in 5D pruritus scale in group B than group A and the difference was statistically significant on day 30, 45 and 60 of follow-up visits.

Similarly, reduction of erythema and scaling between groups were compared on day 0 to day 60. There was reduction in erythema and scaling scores on both groups, however group B participants showed higher reduction in lesser time interval as shown in [Table/Fig-5,6]. The p-value<0.05 on day 45 in erythema and scaling score signified that combination of oral itraconazole plus oral isotretinoin gave early resolution of clinical symptoms.

5D pruritus scale	Group A (n=90)	Group B (n=90)	Unpaired t-test	p-value
Day 0				
Mean±SD	15.98±1.18	15.71±1.42	1.38	0.17
Day 15				
Mean±SD	15.26±1.49	14.99±1.83	1.08	0.29
Day 30				
Mean±SD	11.83±1.46	8.81±1.08	15.77	<0.001
Day 45				
Mean±SD	8.21±1.42	3.96±1.41	20.14	<0.001
Day 60				
Mean±SD	5.47±1.33	2.13±1.32	13.26	<0.001

[Table/Fig-4]: Comparison of 5D pruritus scale.

Erythema score	Group A n (%)	Group B n (%)	Chi-square	p-value
Day 0				
Absent	6 (6.7)	9 (10.0)	1.12	0.8
Mild	54 (60.0)	48 (53.3)		
Moderate	13 (14.4)	15 (16.7)		
Severe	17 (18.9)	18 (20.0)		
Day 15				
Absent	23 (25.6)	28 (31.1)	0.43	0.51
Mild	38 (42.2)	40 (44.4)		
Moderate	18 (20.0)	11 (12.2)		
Severe	11 (12.2)	10 (11.1)		
Day 30				
Absent	38 (42.2)	49 (54.4)	3.03	0.082
Mild	27 (30.0)	28 (31.1)		
Moderate	14 (15.6)	6 (6.7)		
Severe	9 (10.0)	3 (3.3)		
Day 45				
Absent	74 (82.2)	81 (90.0)	3.90	0.048
Mild	11 (12.2)	3 (3.3)		
Moderate	2 (2.2)	0		
Severe	0	0		
Day 60				
Absent	83 (92.2)	79 (87.8)	0.98	0.32
Mild	0	0		
Moderate	0	0		
Severe	0	0		

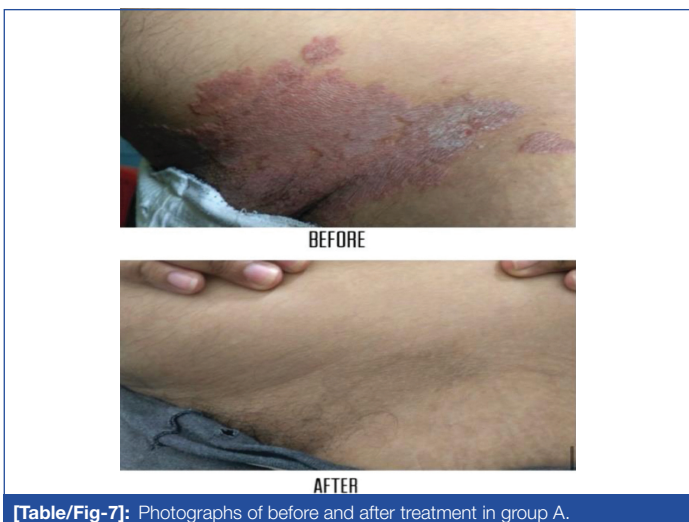[Table/Fig-5]: Comparison of erythema score.

Scaling score	Group A n (%)	Group B n (%)	Chi-square	p-value
Day 0				
Absent	0	1 (1.1)	1.8	0.62
Mild	8 (8.9)	3 (3.3)		
Moderate	13 (14.4)	15 (16.7)		
Severe	69 (76.7)	71 (78.9)		
Day 15				
Absent	3 (3.3)	3 (3.3)	1.07	0.30
Mild	26 (28.9)	36 (40.0)		
Moderate	46 (51.1)	33 (36.7)		
Severe	15 (16.7)	17 (18.9)		
Day 30				
Absent	68 (75.6)	79 (87.8)	3.48	0.062
Mild	9 (10.0)	5 (5.6)		
Moderate	10 (11.1)	2 (2.2)		
Severe	1 (1.1)	0		

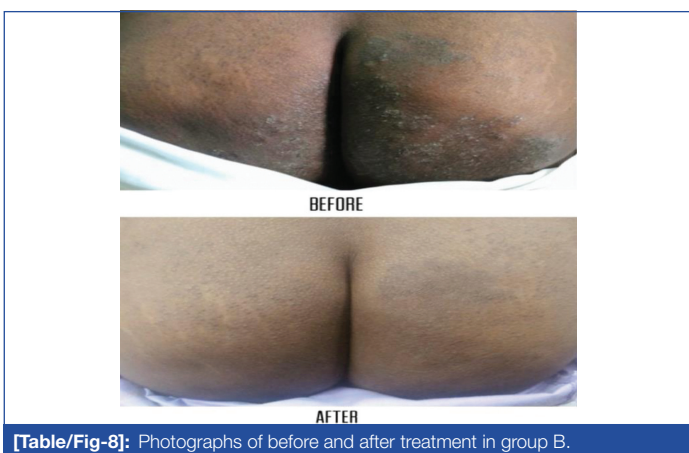
Day 45				
Absent	75 (83.3)	82 (91.1)	4.39	0.036
Mild	11 (12.2)	2 (2.2)		
Moderate	1 (1.1)	0		
Severe	0	0		
Day 60				
Absent	82 (91.1)	79 (87.8)	0.77	0.38
Mild	1 (1.1)	0		
Moderate	0	0		
Severe	0	0		

[Table/Fig-6]: Comparison of scaling score.

Photographic documentation at baseline and on day 60 is shown in [Table/Fig-7,8].



[Table/Fig-7]: Photographs of before and after treatment in group A.



[Table/Fig-8]: Photographs of before and after treatment in group B.

Side-effects were also evaluated and are summarised in [Table/Fig-9]. Eighteen (10%) participants discontinued intervention due to gastritis, hepatic and lipid derangements. Six (3.3%) participants had lip cheilitis managed by application of white petroleum jelly over lips 2-3 times daily. Skin dryness was observed in 6 (3.3%) participants and was advised topical coconut oil application at bed time. Six (3.3%) participants complained of photosensitivity and were advised application of physical protection from sunlight and application of topical calamine lotion in morning time 30 minutes prior to sun exposure.

On subsequent follow-up visits for two months, 10/74 (13.5%) and 2/77 (2.6%) in group A and B respectively had relapse ($\chi^2=6.14$, $p=0.01$).

DISCUSSION

The present study evaluated that combination of oral itraconazole and isotretinoin achieved both mycological and clinical cure faster

Group A (n=90)	Day 0 n (%)	Day 15 n (%)	Day 30 n (%)	Day 45 n (%)	Day 60 n (%)	Statistical Significance	
Adverse effects							
Lip cheilitis	-	-	1 (1.1)	-	-	$\chi^2=6.23$ $p=0.28$	
Skin dryness	-	-	-	1 (1.1)	-		
Photosensitivity	-	-	1 (1.1)	2 (2.2)	4 (4.4)		
Gastritis	-	-	-	1 (1.1)	2 (2.2)		
Hepatic abnormalities	-	-	2 (2.2)	2 (2.2)	4 (4.4)		
Dyslipidaemia	-	-	-	-	1 (1.1)		
Group B (n=90)	Day 0 n (%)	Day 15 n (%)	Day 30 n (%)	Day 45 n (%)	Day 60 n (%)		
Adverse effects							
Lip cheilitis	-	2 (2.2)	3 (3.3)	4 (4.4)	5 (5.6)		
Skin dryness	-	1 (1.1)	2 (2.2)	3 (3.3)	5 (5.6)		
Photosensitivity	-	-	1 (1.1)	2 (2.2)	-		
Gastritis	-	-	-	-	1 (1.1)		
Hepatic abnormalities	-	1 (1.1)	2 (2.2)	3 (3.3)	6 (6.7)		
Dyslipidaemia	-	-	2 (2.2)	3 (3.3)	4 (4.4)		

[Table/Fig-9]: Comparison of side-effects.

with less recurrence rate than monotherapy with oral itraconazole in superficial dermatophytosis. Various studies conducted in the recent past and their comparison with the present study is depicted in [Table/Fig-10] [2,13,17,18].

Mycological cure rate in isotretinoin and itraconazole group in present study was 97.5%. This cure rate was much higher on comparison with previous studies reported by many researchers which signifies that oral isotretinoin given at a dose of 20 mg daily for two months have an additional benefit in management of superficial dermatophytic infections [2,13,17,18]. Moreover, relapse rate noted in the present study was also much lower in isotretinoin and itraconazole group (2.6%) than observed by various researchers in past thereby emphasising the role of oral isotretinoin in prevention of relapse if given for a longer period of time [2,13,17,18]. However, the systemic adverse effects (Gastritis, Hepatic abnormalities, Dyslipidaemia) in both groups was higher in present study (group A-7.7% and group B-12.2%) than previous studies which may be due to higher number of participants enrolled and frequent monitoring of laboratory investigations done [2,13,17,18].

Hence, in the present study addition of oral isotretinoin 20 mg daily for two months induced higher mycological cure with relatively low recurrence rate than previous studies. However, the exact mechanism of action of isotretinoin in superficial dermatophytosis is yet to be explored but previous researches have demonstrated its adjuvant role in dermatophytosis treatment [2,12,13]. Proposed mechanisms are retinoids being immunomodulator boost immune system by stimulating T and B cells to fight against dermatophytosis [19]. Retinoids also modulates epidermal proliferation and differentiation and regulates hyperproliferative epidermis by increasing epidermis cell turnover, this result in clearance and sloughing of growing dermatophytes [20]. Moreover, dermatophytes proliferate in acidic pH, retinoids alter skin pH towards alkalinity thereby inhibiting its growth [21]. The current study observed that addition of isotretinoin had significantly improved the clearance rate with less recurrence.

Limitation(s)

The study was limited by short follow-up period and patients and chief investigator were not blinded.

CONCLUSION(S)

The study concluded that oral isotretinoin can be a good adjuvant with oral itraconazole in achieving faster mycological and clinical

Parameters	Present study, 2023	Arora R et al., 2018 [13]	Rahman MH 2019 [17]	Khattab FM et al., 2021 [2]	Alhamdi DK and Alhamdi KI 2022 [18]
Place of study	Barabanki, Uttar Pradesh	Gujarat	Bangladesh	Egypt	Iraq
No. of participants	180 (randomised into two groups)	76 (randomised into two groups)	40	30	81 (randomised into two groups)
Intervention	Both groups received oral itraconazole 200 mg daily for two months. Group B received an addition of oral isotretinoin 20 mg daily for two months	Both groups were given oral itraconazole 100 mg twice daily+topical clotrimazole cream 1 month. A short course of oral isotretinoin 0.3-0.4 mg/kg was given for two weeks in group B	Oral itraconazole 200 mg twice daily for seven days in a month+oral isotretinoin 20 mg daily for three months	Oral itraconazole 200 mg daily+oral isotretinoin 20 mg daily for six weeks	Oral itraconazole 200 mg daily was given for seven days in a month for two months; group B received an addition of oral isotretinoin 10 mg alternate days for two months.
Result (Mycological cure rate)	Group A-89.2% Group B-97.5%	Group A- 84.2% Group B- 92%	95%	83.3%	Group A-43.9% Group B- 95%
Recurrence rate	Group A-13.5% Group B- 2.6% at 2 months of follow-up period	Group A-21.1%, 26.3%, 26.3% Group B- 7.9%, 7.9%, 7.9% at 2 nd , 4 th , 6 th month respectively	15% during 6 months of follow-up period	28% during 6 months of follow-up period	Group A- 43.9% Group B- 12.8% at 3 months of follow-up period
Adverse effects	Group A-7.7% Group B- 12.2%	Mild (abdominal discomfort and lip cheilitis in Group B) and well tolerated	No Adverse effects noted	Mild (lip cheilitis and skin dryness) and well tolerated	No Adverse effects noted

[Table/Fig-10]: Comparison of present study with various past studies [2,13,17,18].

cure in superficial dermatophytosis with less relapses. Future studies on the pharmacokinetics of oral isotretinoin in dermatophytic infections are the need of the hour due to the emergence of antifungals resistance.

REFERENCES

- Rajagopalan M, Inamadar A, Mittal A, Miskeen AK, Srinivas CR, Sardana K, et al. Expert Consensus on The Management of Dermatophytosis in India (ECTODERM India). *BMC Dermatol.* 2018;18(1):6.
- Khattab FM, Taha M, Elkholy BM. Recent modality in the treatment of recalcitrant dermatophytosis. *Eur J Mol Clin Med.* 2021;8(3):3771-77.
- Havlickova B, Czaika VA, Friedrich M. Epidemiological trends in skin mycoses worldwide. *Mycoses.* 2008;51(4):02-15.
- Salehi Z, Shams-Ghahfarokhi M, Razzaghi-Abyaneh M. Antifungal drug susceptibility profile of clinically important dermatophytes and determination of point mutations in terbinafine-resistant isolates. *Eur J Clin Microbiol Infect Dis.* 2018;37(10):1841-46.
- Monod M. Antifungal resistance in dermatophytes: Emerging problem and challenge for the medical community. *J Mycol Med.* 2019;29(4):283-84.
- Ebert A, Monod M, Salamin K, Burmester A, Uhrlaß S, Wiegand C, et al. Alarming India-wide phenomenon of antifungal resistance in dermatophytes: A multicentre study. *Mycoses.* 2020;63(7):717-28.
- Verma S, Madhu R. The great indian epidemic of superficial dermatophytosis: An appraisal. *Indian J Dermatol.* 2017;62(3):227-36.
- Das S, De A, Saha R, Sharma N, Khemka M, Singh S, et al. The current Indian epidemic of dermatophytosis: A study on causative agents and sensitivity patterns. *Indian J Dermatol.* 2020;65(2):118-22.
- Khurana A, Agarwal A, Agrawal D, Panesar S, Ghadlinge M, Sardana K, et al. Effect of different itraconazole dosing regimens on cure rates, treatment duration, safety, and relapse rates in adult patients with tinea corporis/cruris: A randomized clinical trial. *JAMA Dermatol.* 2022;158(11):1269-78.
- Singh SK, Subba N, Tilak R. Efficacy of Terbinafine and Itraconazole in different doses and in combination in the treatment of tinea infection: A randomized controlled parallel group open labeled trial with clinico-mycological correlation. *Indian J Dermatol.* 2020;65(4):284-89.
- Saoji V, Madke B. Efficacy of salicylic acid peel in dermatophytosis. *Indian J Dermatol Venereol Leprol.* 2021;87(5):671-75.
- Ardeshtna KP, Rohatgi S, Jerajani HR. Successful treatment of recurrent dermatophytosis with isotretinoin and itraconazole. *Indian J Dermatol Venereol Leprol.* 2016;82(5):579-82.
- Arora R, Solanki A. Comparative efficacy of monotherapy of oral itraconazole with oral itraconazole with isotretinoin in chronic and/or resistant superficial dermatophytosis. *Indian J Res.* 2018;7(6):10-13.
- Elman S, Hynan LS, Gabriel V, Mayo MJ. The 5-D itch scale: A new measure of pruritus. *Br J Dermatol.* 2010;162(3):587-93.
- Kanishk UK. To compare efficacy of oral isotretinoin and itraconazole combination with salicylic acid 30% chemical peel for Tinea corporis and Tinea cruris. *Int J Curr Res.* 2019;11(12):8936-39.
- Rhodes J, Clay C, Phillips M. The surface area of the hand and the palm for estimating percentage of total body surface area: Results of a meta-analysis. *Br J Dermatol.* 2013;169(1):76-84.
- Rahman MH. Role of itraconazole pulse therapy with adjuvant isotretinoin in treating recurrent and recalcitrant dermatophytosis. *Gulf J Dermatol Venereol.* 2019;26:2.
- Alhamdi DK, Alhamdi KI. Efficacy and safety of adding low-dose isotretinoin to itraconazole in the treatment of chronic recurrent dermatophytosis among sample of Iraqi patients: An open-labelled therapeutic clinical comparative study. *Indian J Dermatol.* 2022;67:624.
- Asselineau D, Darmon M. Retinoic acid provokes metaplasia of epithelium formed in vitro by adult human epidermal keratinocytes. *Differentiation.* 1995;58(4):297-306.
- Orfanos CE, Zouboulis CC, Almond-Roesler B, Geilen CC. Current use and future potential role of retinoids in dermatology. *Drugs.* 1997;53(3):358-88.
- Thune P, Nilsen T, Hanstad IK, Gustavsen T, Lövig Dahl H. The water barrier function of the skin in relation to the water content of stratum corneum, pH and skin lipids. The effect of alkaline soap and syndet on dry skin in elderly, non-atopic patients. *Acta Derm Venereol.* 1988;68(4):277-83.

PARTICULARS OF CONTRIBUTORS:

- Junior Resident, Department of Dermatology, Venereology, and Leprosy, Hind Institute of Medical Sciences, Safedabad, Barabanki, Uttar Pradesh, India.
- Assistant Professor, Department of Dermatology, Venereology, and Leprosy, Hind Institute of Medical Sciences, Safedabad, Barabanki, Uttar Pradesh, India.
- Professor, Department of Dermatology, Venereology, and Leprosy, Hind Institute of Medical Sciences, Safedabad, Barabanki, Uttar Pradesh, India.

NAME, ADDRESS, E-MAIL ID OF THE CORRESPONDING AUTHOR:

Dr. Deepika Agarwal,
202, Scotia Tower 5, Omaxe Heights, Vibhuti Khand,
Gomti Nagar, Lucknow-226010, Uttar Pradesh, India.
E-mail: dr.deepika2009@gmail.com

PLAGIARISM CHECKING METHODS: [Jain H et al.]

- Plagiarism X-checker: Feb 13, 2023
- Manual Googling: Feb 22, 2023
- iThenticate Software: Mar 29, 2023 (12%)

ETYMOLOGY: Author Origin

AUTHOR DECLARATION:

- Financial or Other Competing Interests: None
- Was Ethics Committee Approval obtained for this study? Yes
- Was informed consent obtained from the subjects involved in the study? Yes
- For any images presented appropriate consent has been obtained from the subjects. Yes

Date of Submission: **Feb 11, 2023**

Date of Peer Review: **Mar 03, 2023**

Date of Acceptance: **Apr 05, 2023**

Date of Publishing: **May 01, 2023**