



Chronic Invasive Aspergillus Sinusitis Affecting the Maxillary Sinus: A Case Report

I. Nourwali¹, M. Elkablawy^{2,3}, M. Hammad⁴ and A. Shamaa^{5,6*}

¹Department of Oral and Maxillofacial Surgery, College of Dentistry, Taibah University, KSA.

²Department of Pathology, College of Medicine, Taibah University, KSA.

³Department of Pathology, College of Medicine, Menoufia University, Egypt.

⁴Department of Preventive Dental Sciences, College of Dentistry, Taibah University, KSA.

⁵Department of Oral Basic and Clinical Science, College of Dentistry, Taibah University, KSA.

⁶Department of Oral Biology, College of Dentistry, Minia University, Egypt.

Authors' contributions

This work was carried out in collaboration between all authors. Author IN performed the clinical diagnosis surgical operation and patient follow up. Author ME carried out the histopathology and examined the slides. Author MH was editing and revising the manuscript. Author AS participated in the surgery, histopathology and drafted the manuscript. All authors read and approved the final manuscript.

Article Information

DOI: 10.9734/BJMMR/2016/26961

Editor(s):

(1) Younes Smani, Clinic Unit of Infectious Diseases, Microbiology and Preventive Medicine, Institute of Biomedicine of Seville (IBiS), University Hospital Virgen del Rocío, Seville, Spain.

Reviewers:

(1) Carol Iyalla, University of Port Harcourt Choba, Nigeria.

(2) Pedro M. Villarreal, Oviedo, Spain.

(3) Alejandro Rojas-Marroquín, Universidad Nacional Autónoma de México, Mexico.

Complete Peer review History: <http://sciencedomain.org/review-history/15283>

Case Study

Received 12th May 2016

Accepted 29th June 2016

Published 4th July 2016

ABSTRACT

Background: Chronic invasive Aspergillus sinusitis is an uncommon fungal infection that usually occurs in immunocompromized patients and rarely in healthy immunocompetent individuals. Chronic invasive Aspergillus sinusitis affecting the maxillary sinus may cause tremendous effects as maxillary bone destruction, displacement of teeth, bronchopulmonary infection and orbital involvement that may lead to proptosis and decreased vision. The maxillary sinus infection may result from direct inhalation of spores and not as a secondary infection from the oral cavity, endodontic treatment, or oro-antral fistulae.

Case Summary: A 30 years old male patient presented to clinic complaining of right sided facial

*Corresponding author: E-mail: Ishamaa@yahoo.com;

swelling and nasal obstruction. Clinical examination, Ortho-Pantomogram (OPG) and Cone Beam Computerized Tomography (CBCT) revealed a right maxillary sinus mass; laboratory investigations exclude presence of any systemic disease. Antrostomy of the lateral sinus wall (Caldwell-Luc surgery) was performed under local anesthesia to remove the sinus lining and mass. The mass was sent for histopathological investigation. The defect of bone was covered with the integrum periostium (the mucosal flap) without any bone graft or meshes. No antifungal drugs were prescribed.

Post operative OPG and CBCT revealed complete removal of the lesion and clearance of the right side nasal air way. The histopathological examination found that the aspergillus Hyphae, fruits bodies and spores are present which confirmed the diagnosis. One year follow-up revealed that there is no recurrent infection; the drifted teeth realigned again and the maxillary sinus returns to its normal size.

Conclusion: Early diagnosis and therapeutic intervention is the key to successful treatment of chronic invasive aspergillosis of the maxillary sinus. Surgical debridement can be done under local anesthesia without antifungal drug prescription and good prognosis was achieved.

Keywords: Aspergillosis; maxillary sinus; healthy (immunocompetent) patient; case report.

ABBREVIATIONS

OPG : Ortho-Pantomogram
CBCT : Cone Beam Computerized Tomography
A. : Aspergillosis
H&E : Hematoxylin and Eosin
PAS : Periodic-Acid-Schiff
LPCB : Lactophenol Cotton Blue
GMS : Gomori Methenamine Silver

1. INTRODUCTION

Aspergillosis of the maxillary sinus may rarely occur as a chronic disease in healthy individuals. This infection is usually confined to a single sinus; it can involve the orbit and may lead to proptosis and decreased vision [1]. Candidiasis has been reported as the first most prevalent fungal infection affecting the maxillary sinus while aspergillosis is the second most common fungal infection and both are frequent inhabitant of upper respiratory tract [2].

Aspergillosis has four clinico-pathological features according to its mucosal and extra mucosal involvement. Two are infectious and two are saprophytic. The infectious forms are chronic indolent and invasive fulminant sinusitis. The saprophytic forms are aspergilloma and allergic aspergillus sinusitis. Another classification done by Rowe Jones in 1994 classified aspergillosis into three chief variants: Invasive, non-invasive and non-invasive destructive type. Invasive type represents true fungal tissue invasion that can be either slow progressive and destructive (non-fulminant) or highly aggressive and lethal (fulminant). The Non-invasive type is further classified into aspergilloma, fungal ball,

mycetoma (usually affecting one sinus) or allergic aspergillus sinusitis (involving more than one sinus). Destructive non-invasive variant is locally destructive but shows no tissue invasion [3].

A. fumigatus species is the most common causative agent and other less common causative species as *A. flavus*, *A. terreus*, *A. parasitius*, *A. repens*, *A. nidulans*, *A. niger* and *A. tubingenensis* [4,5]. They are commonly found in humid areas, damp soil or agricultural environment, on grain, cereal, moldy flour, and organic decaying or decomposing matter. *Aspergillus* grows by budding or branching. The former or conidium, 1–3 µm in diameter, is carried by air and easily inhaled in the lungs. The branching hyphae are 2–5 µm in diameter, split dichotomously at 45° angle, and are best recognized by methanamine silver stain [6]. *Aspergillus* is the most second common fungal pathogen in sinus disease. Spores are ubiquitous, usually introduced by inhalation [7].

Aspergillosis generally occurs after inhalation of spores, that can result in both upper and lower respiratory tract infection- bronchopulmonary aspergillosis [8]. From lungs, infections may spread to the brain, bone or endocardium [9]. Paranasal sinuses, larynx, eyes, ears and the oral cavity may be involved in primary aspergillosis [10]. *A. fumigatus* is the usual agent of sinus aspergillosis, whereas *A. flavus* is more common in invasive lesions in immunosuppressed individuals [11]. Orofacial aspergillosis is relatively common in patients undergoing treatment for malignancies of the blood and blood-forming organs [12-14]. The

outcome of invasive fungal infections depends on various factors such as the clinical condition of the patient, immunological status, pathogenicity and virulence factors of the invading fungal species and the location of the infected area [15].

The purpose of this report is to present a case of aspergillosis of the maxillary sinus in healthy person working in a horse stable and to draw attention to the infection sites, clinical presentation, radiographic and histopathologic investigations and treatment.

2. METHODS

2.1 Patient Information

A 30 years old male patient presented to College of Dentistry Hospital, Taibah University, with one year history of swelling on the right side of cheek, dull pain, facial asymmetry and right nasal side obstruction (Fig. 1A). The patient was not taking any medications and was working in a horse stable. The patient was non-alcoholic and non diabetic.

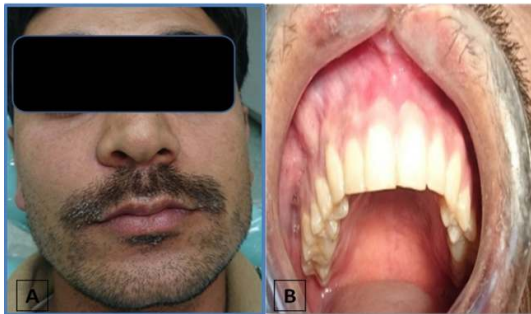

Fig. 1. A, Extra oral photograph showing swelling of right facial side. B, Intra-oral photograph showing swelling on right side maxilla opposite premolar area

2.2 Physical Exam

By clinical intraoral examination there was a swelling apical to the right maxillary canine, first, second premolars and first molar. The right maxillary first premolar was tilted distally; regional lymph nodes were not involved (Fig. 1 B).

2.3 Diagnostic Assessment

Routine laboratory investigations including CBC, fasting blood sugar, virus profile, chest x-ray and consultation with pulmonologist were done to prepare the patient for surgery and to exclude

systemic disease and bronchopulmonary aspergillosis. OPG revealed right maxillary sinus enlargement and radiopacity, displacement of maxillary right premolars with alveolar bone resorption extended anteriorly to the left side lateral incisor. Otherwise all teeth are sound and the periodontal tissue was healthy (Fig. 2). CBCT revealed enlargement and complete obstruction of the right side maxillary sinus, right side nasal airway, bone erosion of the facial wall, alveolar bone and right side palate (Fig. 3).

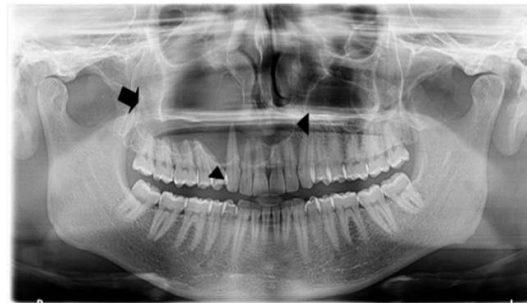

Fig. 2. Preoperative panoramic x-ray showing radiopacity enlarged right maxillary sinus (Arrow), displaced maxillary right first and second premolars anterior extension of the lesion to the left lateral incisor (Arrow head)

2.4 Surgical Procedure

Aspiration of the right maxillary sinus from facial eroded bone area, 2 X 10 cc yellowish fluid were obtained one day prior to surgical procedure. Prophylactic antibiotic were prescribed to the patient. On the day of surgical procedure maxillary nerve block with local infiltration of Sandicaine 2% local anesthesia were administered. Antrostomy of the lateral sinus wall (Caldwell-Luc surgery) was performed removing the sinus lining and the lesion which appear reddish friable with white patches in some area filling the maxillary sinus (Fig. 4), the defect of bone was covered with the integrum periostium (mucosa) without any bone graft or mish. Post operative CBCT revealed complete removal of the lesion and clearance of the right side nasal air way (Fig. 5). The excised specimen was sent to pathology department, college of medicine Taibah University for histopathological examination.

2.5 Histopathology

On gross anatomical finding, the specimen consists of multiple soft tissue that were irregular in shape, friable, cheesy in consistency, and brownish-black in color. Routine Hematoxylin

and Eosin (H&E) stain and three common special stains; Lactophenol Cotton Blue (LPCB), Periodic-Acid-Schiff (PAS) and Gomori Methenamine Silver (GMS) stains were used for confirmation of the diagnosis.

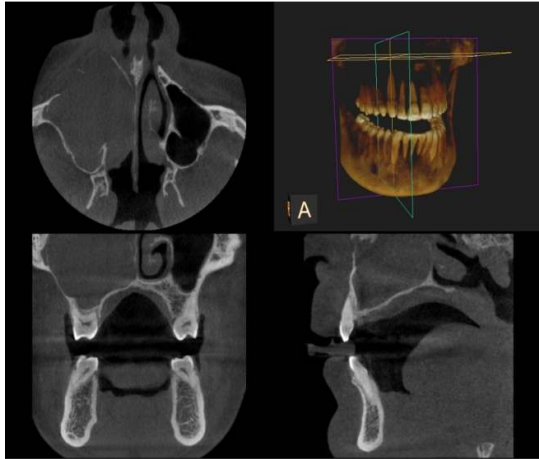


Fig. 3. Preoperative CBCT showing obstructed right nasal side, extension of the lesion in the right maxillary sinus into the medial and lateral sinus walls, with bone erosion of the facial, lateral, palatal walls and alveolar bone extended anteriorly to the left side above the central and lateral incisors

Examination of hematoxylin and eosin-stained sections revealed a degenerated sinus lining with some pseudostratified ciliated columnar epithelial cells. Basement membrane was not intact. Underlying connective tissue was fibrocellular with little chronic inflammatory cell infiltrate. Another tissue section showed degenerated

areas surrounded by fibrous tissue, Fruiting bodies and spores. (Fig. 6 A&B)

Lactophenol Cotton Blue (LPCB) stain showed the aspergillus Hyphae, fruits bodies and spores stained dark blue (Fig. 7 A & B). Periodic-acid-Schiff (PAS) reagents stained the fungus with purple-magenta color (Fig. 8A) while Gomori Methenamine Silver (GMS) stain outlined the fungal cell wall from brown to black color (Fig. 8 B). After reviewing clinical, radiographic, and histopathological findings, diagnosis of chronic invasive aspergillosis of Maxillary sinus was made.

2.6 Follow-up and Out-comes

Clinical and radiographic OPG and CBCT follow-up of the patient over one year revealed no recurrent infections, canine and premolars return to its normal mesiodistal angulation and the sinus returns to its normal size and shape (Fig. 9).

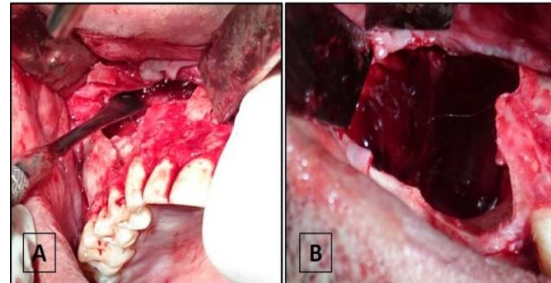


Fig. 4. Antrostomy of the lateral sinus wall (Caldwell-Luc surgery) A. during and B. after removal of the lesion

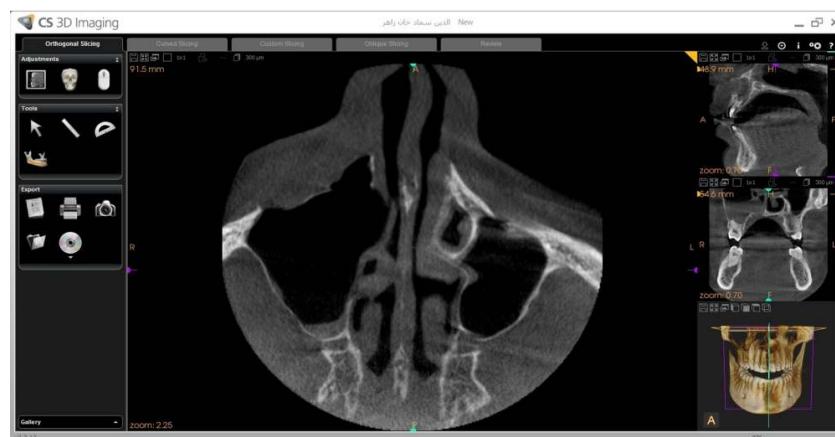

Fig. 5. CBCT after surgery showing complete removal of the lesion and clearance of the right side nasal air way

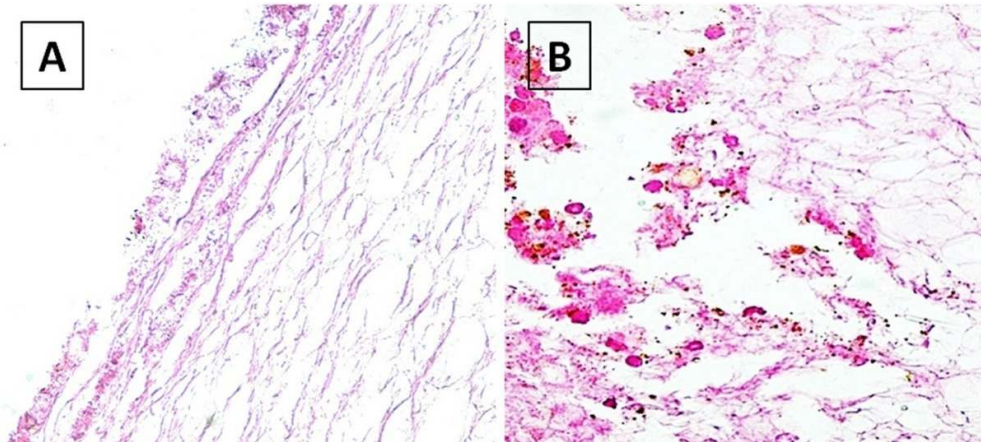


Fig. 6. A, degenerated sinus lining. B, conidia and spores surrounded by degenerated fibrous tissue (H&E X 400)

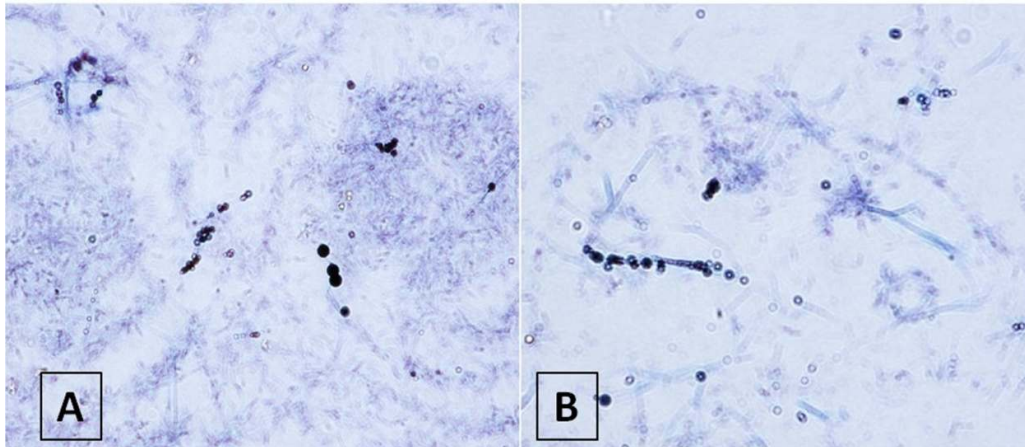


Fig. 7. A, conidium and ascospores. B, the aspergillus septate hyphae (LPCB X400)

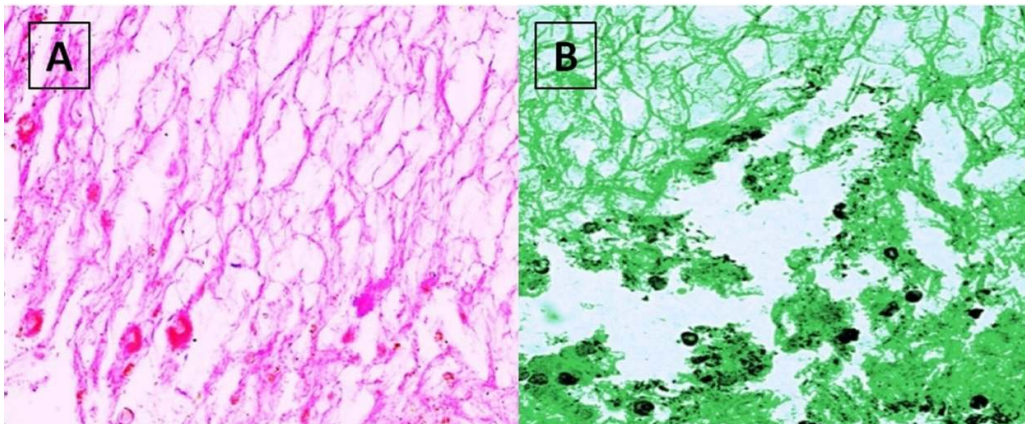


Fig. 8. A, PAS stained the fungus with purple-magenta color. B, Gomori Methenamine Silver (GMS) stain outlined the fungal cell wall from brown to black color

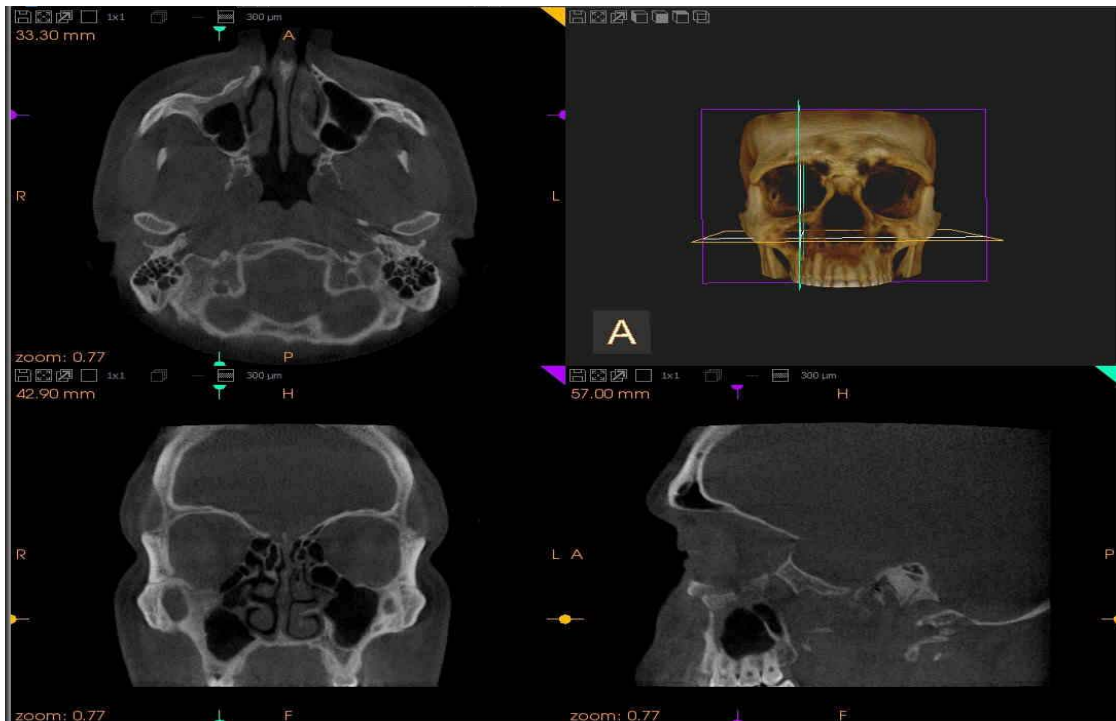

Fig. 9. CBCT one year follow-up showed no recurrent infections, teeth realignment and the sinus retain its normal size and shape with good prognosis

3. RESULTS AND DISCUSSION

Chronic invasive *Aspergillus* sinusitis affecting the maxillary sinus are common in immunocompromised patients; on the other hand, they should be recognized in immunocompetent persons who are not expected to be infected with fungi to avoid significant complications that may occur due to this infection. Suspicion can arise in cases of purulent rhinosinusitis which do not respond to antibiotics, and on the basis of clinical and radiological features. Most invasive aspergillosis is caused by *A. fumigatus* [80-90%]; *A. flavus* [5-10%], *A. niger* [1-5%] and *A. terreus* [1%] are less common [16]. *Aspergillus fumigatus* is the most common organism in immunocompetent patients too [17].

Aspergillosis can cause serious complications if not diagnosed and treated early. It includes intramaxillary growth, destruction of the maxilla and alveolar bone, displacement of the teeth and extension into the peripheral soft tissues of maxilla. Previous studies, described some cases of intraorbital and intracranial growth along the base of the skull leading to cavernous sinus thrombosis and brain infection [18]. Intracranial

and intraorbital extension decrease the survival rate and increase surgical morbidity [19].

Aspergillosis generally occurs after inhalation of spores, that can result in both upper and lower respiratory tract infection (bronchopulmonary aspergillosis) [8] which is similar to this patient; A 30 years old male patient working in a horse stable in direct contact with dead leaves, decaying vegetable matter and stored grains that may contains the mold spores. *Aspergillus* hyphae invade host tissues through the release of various toxins. These include various proteases, phospholipases, hemolysins, gliotoxin, aflatoxin, phthioic acid and other toxins [20]. The hyphal elements of the fungus may invade the mucosa and penetrate the walls of small to medium-sized blood vessels, producing thrombosis, infarction and necrosis, finally leading to systemic spread [21]. From our previous experience, cases like this case can be treated through resection using a routine lateral antrostomy (Caldwell-Luc surgery) under local anesthesia without the need of antifungal drugs that will reduce the cost and avoid the adverse effects of these drugs with good prognostic results [22].

4. CONCLUSION

Early History, diagnosis and therapeutic intervention is the key to successful treatment of invasive aspergillosis. The diagnosis of maxillary sinus aspergillosis depends mainly on the clinical circumstances of the infection, the anatomic site, and the microscopic findings. However, from a practical standpoint treatment may need to be initiated immediately to prevent further complications. Surgical treatment can be done under local anesthesia without need to antifungal drugs and good prognosis was achieved. Workers in direct contact with dead leaves, decaying vegetable matter, stored grains should carry face mask or mechanical barrier to avoid Aspergillus infection.

CONSENT

Written informed consent was obtained from the patient for publication of this case report and accompanying images.

ETHICAL APPROVAL

All authors hereby declare that all experiments have been examined and approved by Taibah University College of Dentistry Research Ethics Committee (TUCD REC) organized and operated according to the Saudi national regulation of the national bioethics committee and have therefore been performed in accordance with the ethical standards laid down in the 1964 Declaration of Helsinki.

ACKNOWLEDGEMENTS

We would like to thank dental assistants Irshad Ahmed oral surgery department and Ajaz Wani oral radiology department, College of Dentistry, Taibahu University, for their kind and professional assistance during the operation and follow up of the patient.

COMPETING INTERESTS

Authors have declared that no competing interests exist.

REFERENCES

1. Warder FR, Chikes PG, Hudson WR. Aspergillosis of the paranasal sinuses. Arch Otolaryngol. 1975;101(11):683-5.
2. Hartwick RW, Batsakis JG. Sinus aspergillosis and allergic fungal sinusitis. Ann Otol Rhinol Laryngol. 1991;100:427-30.
3. Destructive noninvasive paranasal sinus aspergillosis: Component of a spectrum of disease. Rowe-Jones JM, Moore-Gillon VJ. Otolaryngol. 1994;23(2):92-6.
4. Scully C, de Almeida OP. Orofacial manifestations of the systemic mycoses. J Oral Pathol Med. 1992;21(7):289-94. (Review).
5. Bathoorn E, Escobar Salazar N, Sepehrkhoy S, Meijer M, de Cock H, Haas PJA. Involvement of the opportunistic pathogen *Aspergillus tubingensis* in osteomyelitis of the maxillary bone: A case report. BMC Infectious Diseases [E]. 2013;13:59:1.
6. Sharma OP, Chwogule R. Many faces of pulmonary aspergillosis. Eur Respir J. 1998;12:705-15.
7. Warder FR, Chikes PG, Hudson WR. Aspergillosis of the paranasal sinuses. Arch Otolaryngol. 1975;101:683-5.
8. Dreizen S, Keating MJ, Beran M. Orofacial fungal infections. Nine pathogens that may invade during chemotherapy. (353-44). Postgrad Med. 1992;91:349-50:357-60.
9. Benson-Mitchell R, Tolley N, Croft CB, Gallimore A. Aspergillosis of the larynx. J Laryngol Otol. 1994;108:883-5.
10. Myoken Y, Sugata T, Kyo TI, Fujihara M. Pathological features of invasive oral aspergillosis in patients with hematologic malignancies. J Oral Maxillofac Surg. 1996;54:263-70.
11. Emmanuelli JL. Infectious granulomatous diseases of the head and neck. Am J Otolaryngol. 1993;14:155-67.
12. Chambers MS, Lyzak WA, Martin JW, Lyzak JS, Toth BB. Oral complications associated with aspergillosis in patients with a hematologic malignancy. Presentation and treatment. Oral Surg Oral Med Oral Pathol Oral Radiol Endod. 1995;79:559-63.
13. Dreizen S, Bodey GP, McCredie KB, Keating MJ. Orofacial aspergillosis in acute leukemia. Oral Surg Oral Med Oral Pathol. 1985;59:499-504.
14. Sugata T, Myoken Y, Kyo T, Fujihara M. Invasive oral aspergillosis in immunocompromised patients with

- leukemia. J Oral Maxillofac Surg. 1994;52:382–6.
15. Ramana KV, Kandi S, Bharatkumar PV, Sharada CH, Rao R, Mani R, et al. Invasive fungal infections: A comprehensive review. Am J Infect Dis Microbiol. 2013;1:64–9.
 16. Akhaddar A, Gazzaz M, Albouzidi A, Lmimouni B, Elmostarchid B, Boucetta M. Invasive *Aspergillus terreus* sinusitis with orbitocranial extension: Case report. Surg Neurol. 2008;69(5):490-5:discussion 495.
 17. Kameswaran M, al-Wadei A, Khurana P, Okafor BC. *Rhinocerebral aspergillosis*. J Laryngol Otol. 1992;106(11):981-5.
 18. Arora V, Nagarkar NM, Dass A, Malhotra A. Invasive rhino-orbital aspergillosis. Indian J Otolaryngol Head Neck Surg. 2011;63:325–9.
 19. Beatriz Peral-Cagigal, Luis-Miguel Redondo-González, Alberto Verrier-Hernández. Invasive maxillary sinus aspergillosis: A case report successfully treated with voriconazole and surgical debridement. J Clin Exp Dent. 2014;6(4):e448–e451.
 20. Denning DW. Invasive aspergillosis. Clin Infect Dis. 1998;26:781–805.
 21. Dreizen S. Oral complications of cancer therapies: Description and incidence of oral complications. Monogr Natl Cancer Inst. 1990;9:11–5.
 22. Schedel I. New medications for treatment of systemic mycoses]. Internist (Berl). 2005;46(6):659-70.

© 2016 Nourwali et al.; This is an Open Access article distributed under the terms of the Creative Commons Attribution License (<http://creativecommons.org/licenses/by/4.0>), which permits unrestricted use, distribution, and reproduction in any medium, provided the original work is properly cited.

Peer-review history:

The peer review history for this paper can be accessed here:
<http://sciencedomain.org/review-history/15283>