



Laparoscopic Extraperitoneal Repair of Incarcerated Bladder Inguinal Hernia

Fahrettin Acar^{1*}, Bayram Çolak¹ and Mustafa Sahin¹

¹Department of Surgery, Faculty of Medicine, Selcuk University, Konya, Turkey.

Authors' contributions

This work was carried out in collaboration among all authors. Author FA designed the study, performed the statistical analysis, wrote the protocol and wrote the first draft of the manuscript. Authors FA and MŞ managed the analyses of the study. Author BÇ managed the literature searches. All authors read and approved the final manuscript.

Article Information

Editor(s):

(1) Dr. José Francisco de Sales Chagas, Professor, Sao Leopoldo Mandic Medical School, Brazil.

Reviewers:

(1) Chanchal Mangla, New York Presbyterian Brooklyn Methodist Hospital, USA.

(2) Rahul Gupta, Synergy Institute of Medical Sciences, India.

(3) Heber Anandan, Dr. Agarwal's Eye Hospital, India.

Complete Peer review History: <http://www.sdiarticle4.com/review-history/54837>

Case Study

Received 11 December 2019

Accepted 18 February 2020

Published 24 February 2020

ABSTRACT

Introduction: Cases of inguinal bladder hernia are rare, with bladder involvement seen in 1–4% of inguinal hernias. Surgical repair is currently the standard treatment, and careful surgical planning is necessary to avoid complications including bladder injury.

Case Presentation: A 62-year-old man presented to our Emergency Department with 15-day history of progressively worsening right lower quadrant pain, groin bulge and dysuria. Physical exam revealed an irreducible right inguinal hernia associated with urinary urgency on attempted reduction. Magnetic resonance imaging was ordered and demonstrated inguinal hernia with bladder protrusion into the right scrotum. The patient underwent Laparoscopic extraperitoneal reduction and hernia repair and made a quick postoperative recovery without complications.

Discussion: Inguinal bladder hernia most often presents in older, obese males and clinicians should have a high index of suspicion when assessing patients with inguinal hernia. Preoperative diagnosis based on history, physical and radiologic imaging allow for careful surgical planning and prevention of severe complications including bladder injury and leakage.

Conclusion: We present a case report of incarcerated inguinal bladder hernia in a middle-aged man that presented as right lower quadrant pain, groin pain and dysuria. The hernia was Laparoscopic extraperitoneal repair reduced and the defect repaired without complications.

*Corresponding author: E-mail: drfacar@hotmail.com;

Keywords: Inguinal bladder hernia; laparoscopic; urinary system; surgical correction.

1. INTRODUCTION

Although incidence of bladder and inguinal hernia can be seen in 1-4%, incarcerated bladder inguinal hernia is very rare [1]. The contents of the hernia sac can range from a simple diverticulum to the entire bladder, ureter and prostate with intestinal segments [1,2]. While small bladder hernias generally do not cause any complaints, patients with large or incarcerated bladder hernia may present with symptoms such as lower urinary tract symptoms, intermittent scrotal swelling and biphasic voiding. Symptomatic patients usually require surgical correction. We aimed to present the laparoscopic extraperitoneal repair of an incarcerated bladder hernia.

2. CASE REPORT

A 62-year-old male patient presented to our outpatient clinic with complaints of intermittent right groin swelling and lower urinary tract for 15 days. In the history, it was learned that the

complaints first started with swelling in the right groin and then the swelling did not disappear and caused pain. It was learned that the patient had diabetes mellitus and hypertension which had been under oral control for 10 years. Body mass index was 26 kg/m². Physical examination revealed an irreducible swelling of approximately 7-8 cm in the right groin that did not descend to the scrotum. Ultrasonography revealed suspected bladder hernia and cystography was planned. On cystography, approximately one quarter of the bladder was incarcerated from the right inguinal hernia site. Magnetic resonance imaging (MRI) confirmed that there was no evidence of malignancy in the hernia sac and that there was continuous incarcerated hernia in the bladder (Fig. 1). The patient underwent laparoscopic extraperitoneal reduction of the incarcerated bladder directly from the hernia site and hernia repair with mesh. There was no postoperative problem and the patient was sent to the second postoperative home. On the 15th day, the cystography showed normal bladder.

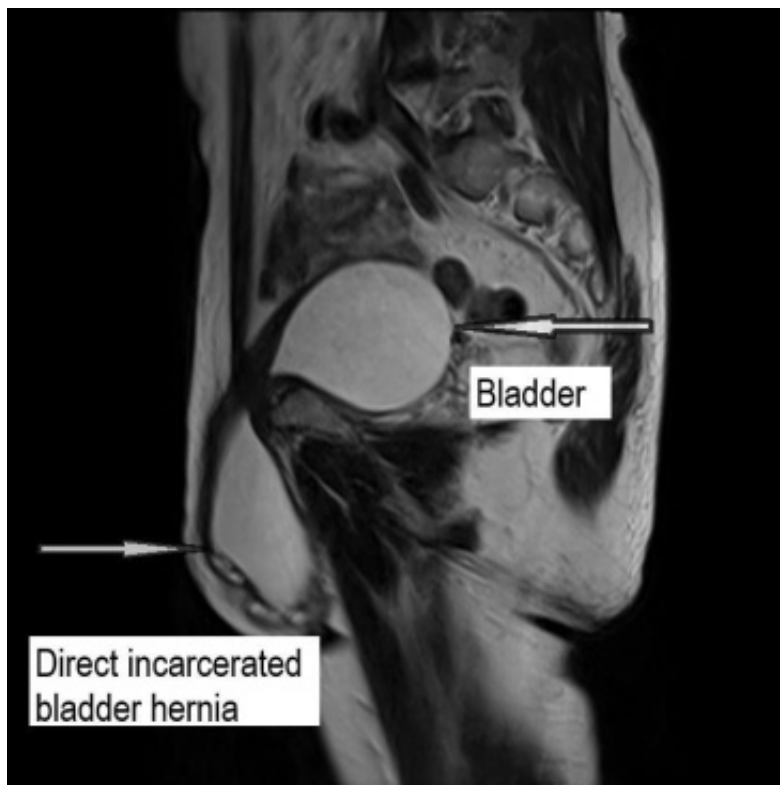


Fig. 1. Magnetic resonance image of incarcerated bladder hernia

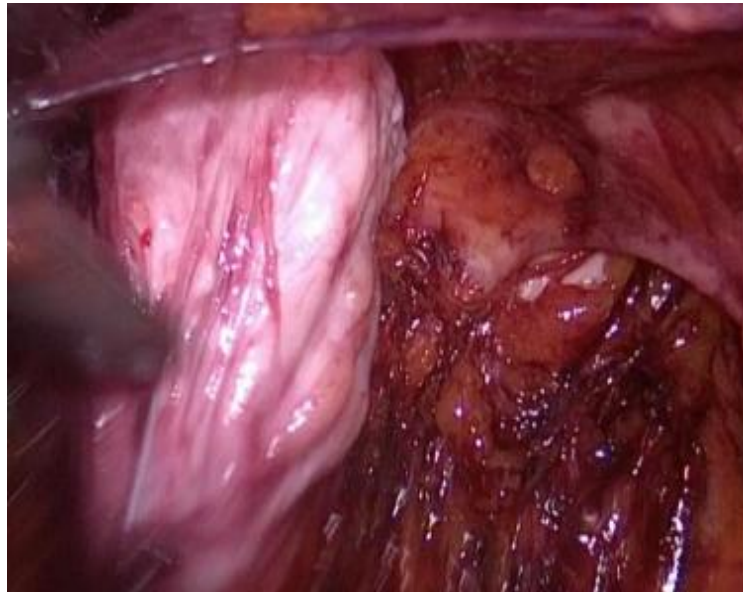

Fig. 2. Intraoperative image of incarcerated bladder hernia

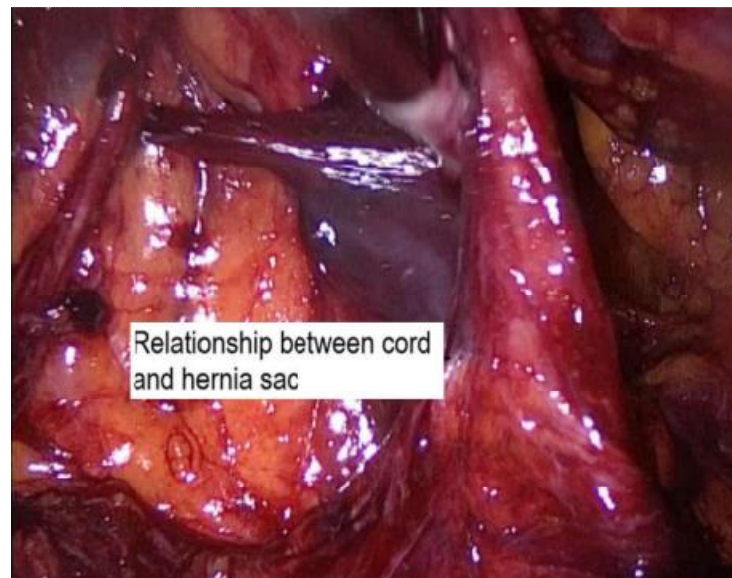


Fig. 3. Separation of hernia pouch from inguinal cord

The preperitoneal area was enlarged by inflating the balloon in the Bogros area by passing the skin, subcutaneous and rectus anterior sheath through a 1.5 cm incision made from the midumbilical midline and then extending the 10 mm balloon dilator through the rectus sheath to the pubis. After the CO₂ was delivered through the port, 2 more 5 mm trocar was entered under the umbilical middle line under the sight of the camera so as not to interfere with each other. The dissection area was enlarged until

symphysis pubis and inferior epigastric vessels were seen on the inner side and the other margin of the psoas muscle appeared on the anterior superior of the spina iliac. An incarcerated bladder was seen in the direct hernia area (Fig. 2) and it was reduced by blunt dissection to the anatomic position. The bladder was inflated by giving water through the foley catheter and bladder integrity was checked. There were no strangulation with ischemia or infarction of bladder. After the hernia sac was rotated at the

level of the inner inguinal ring, the separation of the spermatic cord and vessels and the reduction of the whole hernia sac were performed (Fig. 3). The mesh of appropriate size was laid to cover the potential hernia areas, and it was fixed to the pubic bone and Cooper ligament on the inner side and transverse aponeurosis at the iliac bone level on the outer side (Fig. 4). The process was terminated by providing CO₂ desufflation under the camera view. The patient was discharged without any postoperative complications such as sepsis, renal failure, hydronephrosis.

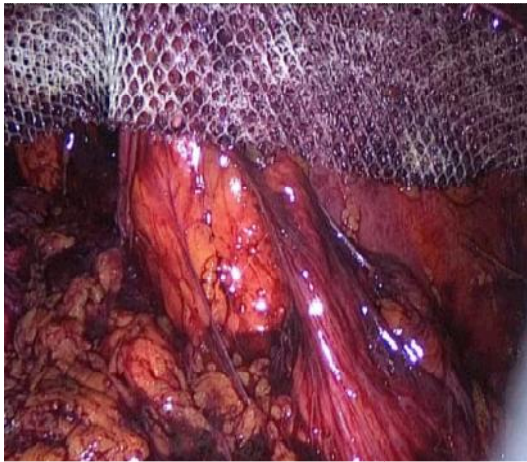


Fig. 4. Laparoscopic repair with extraperitoneal mesh

3. DISCUSSION

Bladder hernia develops in 4% of inguinal hernias. Although most bladder hernias are asymptomatic and detected intraoperative, they may also appear as incarcerated inguinal hernias [1-5]. Bladder hernias are thought to be due to chronic urinary obstruction, obesity, decreased bladder tone and weakness of the pelvic muscles [1] Ersoy, et al. reported a case of giant inguinoscrotal bladder hernia developing as a late complication of inguinal herniorrhaphy [2]. Inguinal bladder hernias are usually seen in the elderly and are more common on the right side [1]. In our case, it was seen in the elderly and right groin. Bladder hernias are classified as intraperitoneal, extraperitoneal and paraperitoneal according to their relationship with the peritoneum. Paraperitoneal hernia is the most common type [6] as seen in our patient. Intraperitoneal hernias are extremely rare. The clinical presentation of scrotal bladder hernias is generally related to the size and content of the hernia. While small ones do not usually cause

any complaints, large bladder hernias may present with hematuria, pain, biphasic voiding, renal failure, incarceration or perforation [4]. In a 2008 study, 11.2% of incarcerated bladder hernias were shown to be associated with urologic malignancies [7]. Das, et al. reported a case of transitional cell carcinoma developing in herniated bladder diverticulum [4]. In our case, we ruled out malignancy in the first stages with MRI. Truss, et al. reported a case of scrotal bladder hernia involving the entire bladder, prostate, urethra, and both ureters leading to uremia [3,8]. Ultrasound is the first imaging modality to be used in the differential diagnosis of scrotal swelling. The hypoechoic appearance adjacent to the testis extending into the inguinal canal is the main finding in ultrasound. Ultrasound also allows the evaluation of the upper urinary system. Retrograde/voiding urethrocytography is the best diagnostic imaging modality in the diagnosis of bladder hernia. Computed tomography and MRI provide additional information for hernia content and assist in surgical planning [9]. Preoperative recognition of hernia sac contents is important to prevent serious surgical complications. Gomella, et al. reported that unrecognized bladder injuries during hernia repair may lead to serious complications such as hematuria, sepsis and fistula formation in 38% of cases [1]. In the treatment of scrotal bladder hernias, inguinal placement of hernia in the anatomical position of the bladder and repair with mesh or non-mesh is the preferred method. Moufid, et al. reported that the hernia can be repaired successfully in cases where the use of mesh is avoided due to bleeding or the possibility of urine contact or leakage to the surgical area [10]. In addition, mesh repair is recommended for inguinal hernia patients [11]. Partial cystectomy is recommended in the presence of necrotic bladder tissue or bladder diverticulum, when hernia neck is smaller than 0.5 cm or incidental bladder tumor is detected within the hernia [1]. Various methods have been supported in the management of bladder inguinal hernia including open procedure, laparoscopic methods, and robotic surgery. Open surgery is the most common surgical procedure used, made in 80.4% of bladder inguinal hernia cases [11]. Laparoscopic repair of incarcerated inguinal hernia has been increasingly accepted in recent years. In laparoscopic repair of incarcerated direct or indirect hernias, it is recommended that in some sources, the incision of the defect area or blunt dissection can be reduced in a controlled manner.

4. CONCLUSION

Patients presenting with incidental inguinal hernia should be suspected of having a bladder herniation, especially if urinary system complaints are present and in order to minimize the intraoperative complication, it is necessary to clarify the diagnosis and perform an operation plan with preoperative evaluation. The laparoscopic extraperitoneal bladder can be removed from the hernia sac without any complications and placed in its anatomical place and repaired by mesh.

CONSENT

The patients written consent was taken for this study.

ETHICAL APPROVAL

It is not applicable.

COMPETING INTERESTS

Authors have declared that no competing interests exist.

REFERENCES

1. Gomella LG, Spires SM, Burton JM, Ram MD, Flanigan RC. The surgical implications of herniation of the urinary bladder. Arch Surg. 1985;120:9647.
2. Ersoy E, Karagüzel E, Akgül T, Ayyıldız A, Germiyanoğlu C. Dev inguinoskrotal mesane hernisi. Türk Üroloji Dergisi. 2009;35(3):2667.
3. Truss F, Zimmermann A. Uremia caused by giant scrotal hernia and bladder herniation. Urologie A. 1981;20(3):15961.
4. Das CJ, Debnath J, Thulkar SP, Kumar L, Vashist S. Transitional cell carcinoma in a herniated vesical diverticulum. Br J Radiol. 2007;80(957):e2279.
5. Stewart CA, Hung GL, Olsen B, Bennett C. Urinary bladder herniation into the scrotum. Incidental demonstration on bone scintigraphy. Clin Nucl Med. 1996;21(6):498.
6. Bernaerts A, Beeck BO, Hoekx L, Parizel PM. Paraperitoneal indirect inguinal bladder hernia: MR demonstration. Abdom Imaging. 2005;30(6):685-8
7. Kraft KH, Sweeney S, Fink AS, Ritenour CWM, Issa MM. Inguinoscrotal bladder hernias: Report of a series and review of the literature. Can. Urol. Assoc. J. 2008; 2(6):619–623.
8. Papatheofani V, Beaumont K, Nuessler NC. Inguinal hernia with complete urinary bladder herniation: A case report and review of the literature. J Surg Case Rep. 2020;2020(1):321.
9. Branchu B, Renard Y, Larre S, Leon P. Diagnosis and treatment of inguinal hernia of the bladder: A systematic review of the past 10 years. Turk. J. Urol. 2018;44(5): 384–88.
10. Moufid K, Touiti D, Mohamed L. Inguinal bladder hernia: Four case analysis. Rev Urol. 2013;15:326-2170.
11. Hernia Surgery Group International guidelines for Groin Hernia Management. Hernia. 2018;22(1):1–165.

© 2020 Acar et al.; This is an Open Access article distributed under the terms of the Creative Commons Attribution License (<http://creativecommons.org/licenses/by/4.0>), which permits unrestricted use, distribution, and reproduction in any medium, provided the original work is properly cited.

Peer-review history:

The peer review history for this paper can be accessed here:
<http://www.sdiarticle4.com/review-history/54837>