

Mycobacterium chimaera Associated Haemophagocytic Lymphohistiocytosis

Joseph Butterworth

Department of Acute Medicine, University Hospital Coventry and Warwickshire, Coventry, UK

Email: joebutterworth@doctors.org.uk

How to cite this paper: Butterworth, J. (2016) *Mycobacterium chimaera* Associated Haemophagocytic Lymphohistiocytosis. *Open Journal of Blood Diseases*, 6, 53-58. <http://dx.doi.org/10.4236/ojbd.2016.64008>

Received: October 17, 2016

Accepted: November 14, 2016

Published: November 17, 2016

Copyright © 2016 by author and Scientific Research Publishing Inc. This work is licensed under the Creative Commons Attribution International License (CC BY 4.0).

<http://creativecommons.org/licenses/by/4.0/>



Open Access

Abstract

Haemophagocytic lymphohistiocytosis (HLH) is a potentially fatal condition in which abnormal activation of the immune system results in haemophagocytosis, inflammation and tissue damage. This results in a variety of signs and symptoms but most commonly fever, lymphadenopathy, splenomegaly, cytopenias, hyperferritinaemia and hypertriglyceridaemia. There are multiple reports of acquired HLH developing on a background of disseminated *Mycobacterium* infection. Simultaneously, since 2011, cases of invasive cardiovascular infection caused by *Mycobacterium chimaera* (*M. chimaera*) in patients having previously undergone cardiac surgery in Europe have been reported. We report a case of acquired HLH occurring one year after open-heart surgery to place a prosthetic valve due to *M. chimaera*.

Keywords

Haemophagocytic Lymphohistiocytosis, *Mycobacterium chimaera*

1. Introduction

Mycobacterium Avium Complex (MAC) are a group of mycobacteria, which are found widely in the environment such as in soil and drinking water and are generally not harmful to the majority of healthy people [1]. They occasionally cause respiratory infections, or more fulminant infections in immunosuppressed individuals [1]. The US Food and Drug Administration (FDA) have recently issued an alert relating to the association of non-tuberculous mycobacterial infections such as MAC with heater-cooler devices primarily used in cardiothoracic surgical procedures [2]. The majority of cases have been prosthetic heart valves that have become infected either through contaminated water entering the devices or aerosolised bacteria transmitted through exhaust vents [2]. In some cases, patients presented with infections several months to years after their surgical procedure [2] [3].

Hemophagocytic lymphohistiocytosis (HLH) is a frequently fatal and underdiagnosed disease involving a final common pathway of hypercytokinemia, which can result in end-organ damage and death [4]. Secondary HLH presents with a systemic inflammatory response syndrome (SIRS) and diagnosis requires five of the following eight criteria to be met; 1) fever, 2) cytopenia of two lines, 3) hypertriglyceridemia and/or hypofibrin-ogenemia, 4) hyperferritinemia (>500 microg/L), 5) hemophagocytosis, 6) elevated soluble interleukin-2 receptor (CD25), 7) decreased natural killer-cell activity, and 8) splenomegaly. There have been case reports confirming links between HLH and disseminated MAC or secondary to *Mycobacterium tuberculosis*, however no documented case with *M. chimaera* [5]. Typical patient presentation involves unexplained fevers, weight loss and pancytopenia. We present a case of HLH secondary to *M. chimaera* infection of a prosthetic heart valve.

2. Case Presentation

2.1. Case History

A 72-year-old Caucasian gentleman was admitted to hospital with a progressive pancytopenia and a one-month history of unintentional weight loss and fevers (temperature >38°). The patient had a past medical history of a prosthetic aortic valve replacement (AVR) for critical aortic stenosis in 2014. On clinical examination there was no stigmata of endocarditis with normal heart sounds however a spleen was palpable (Table 1).

2.2. Investigations

A transoesophageal echocardiogram revealed an intact tissue aortic valve with normal flow and no visible vegetations. Full blood count revealed pancytopenia (Hb 89 g/L, WBC $1.87 \times 10^9/L$, plts $69 \times 10^9/L$) and peripheral blood film showed red cell anisopoikilocytosis, acanthocytes and pencil cells with a negative haemolysis screen and mildly abnormal haematinics (Vitamin B12 337 pg/mL, folate 2.8 ng/mL, iron 8.0 mcg/dL).

In view of pancytopenia and splenomegaly, HLH was suspected and further biochemistry results showed an elevated ferritin 1677 ng/ml and triglyceride of 2.1 mg/dL. A bone marrow biopsy was performed, demonstrating the presence of numerous phagocytosing histiocytes suspicious of macrophage activation and non-necrotic microgra-

Table 1. Patient demographics.

Patient Characteristics	
Age	72 years old
Ethnicity	Caucasian
Medical History	Tissue Aortic Valve replacement
Presenting symptoms	Fever and weight loss
Examination findings	Pyrexia and splenomegaly

nulomas raising concern for an infectious disease precipitant (**Figure 1**). Based on these findings our patient satisfied the clinical, laboratory and histopathological criteria for HLH (**Table 2**).

Radiological imaging only revealed mild splenomegaly with no occult malignancy and virology testing including Hepatitis B, C and HIV was negative. Microbiology investigations with serial peripheral blood cultures performed persistently isolated *Mycobacterium* Intracellulare, later confirmed to be *M. chimaera*.

2.3. Management and Case Progression

To combat the *Mycobacterium* infection, the patient was commenced on a prolonged course of combination of antibiotics including Clarithromycin, Rifampicin, Ethambutol and Amikacin. Intravenous Immunoglobulin (IVIg) was given weekly to inhibit haemophagocytosis, resulting in improvement in pancytopenia, hyperferritinaemia (**Figure 2**) and constitutional symptoms.

Table 2. 2004 HLH diagnostic criteria [5].

Criteria	Patient Characteristics
Fever	Yes
Splenomegaly	Yes
Cytopenia (affecting ≥ 2 of 3 lineages)	Yes
Hypertriglyceridemia and/or hypofibrinogenemia	Yes
Histopathological criteria	Yes
Low or absent NK cell activity	Not Applicable
Ferritin ≥ 500 micrograms/L	Yes
Soluble CD 25 ≥ 2400 U/ml	Not Applicable
Molecular Diagnosis	Not Applicable

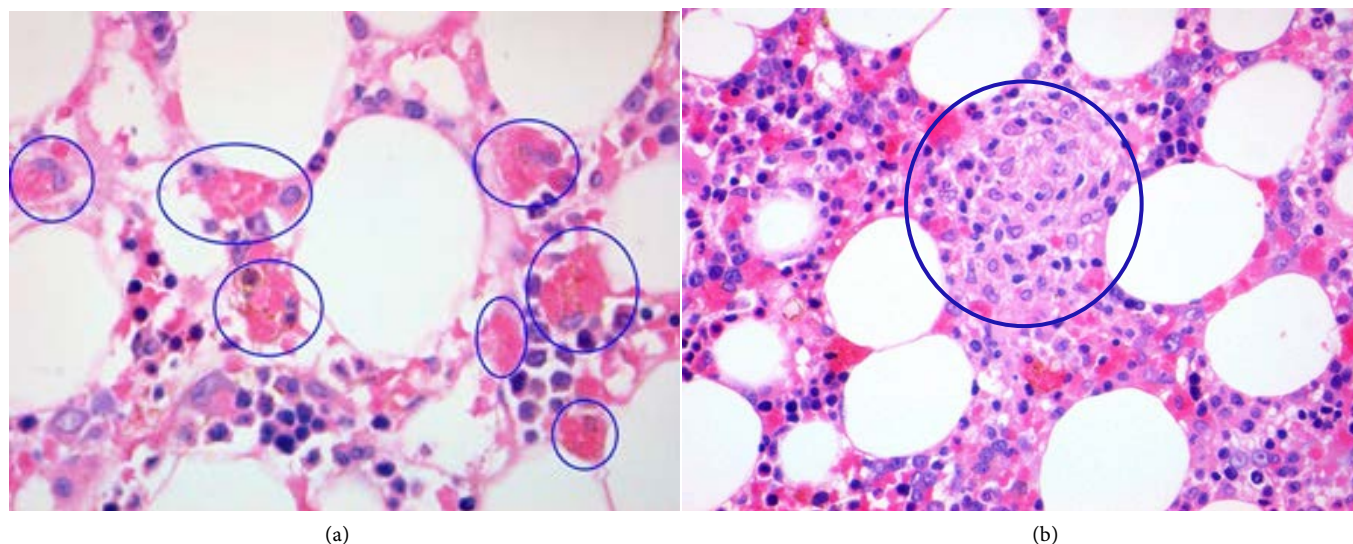


Figure 1. Bone marrow trephine specimen showing; (a) numerous histiocytes packed with red blood cells (circled) $\times 40$ lens (b) microgranuloma and phagocytosis of erythrocytes (circled) $\times 100$ lens.

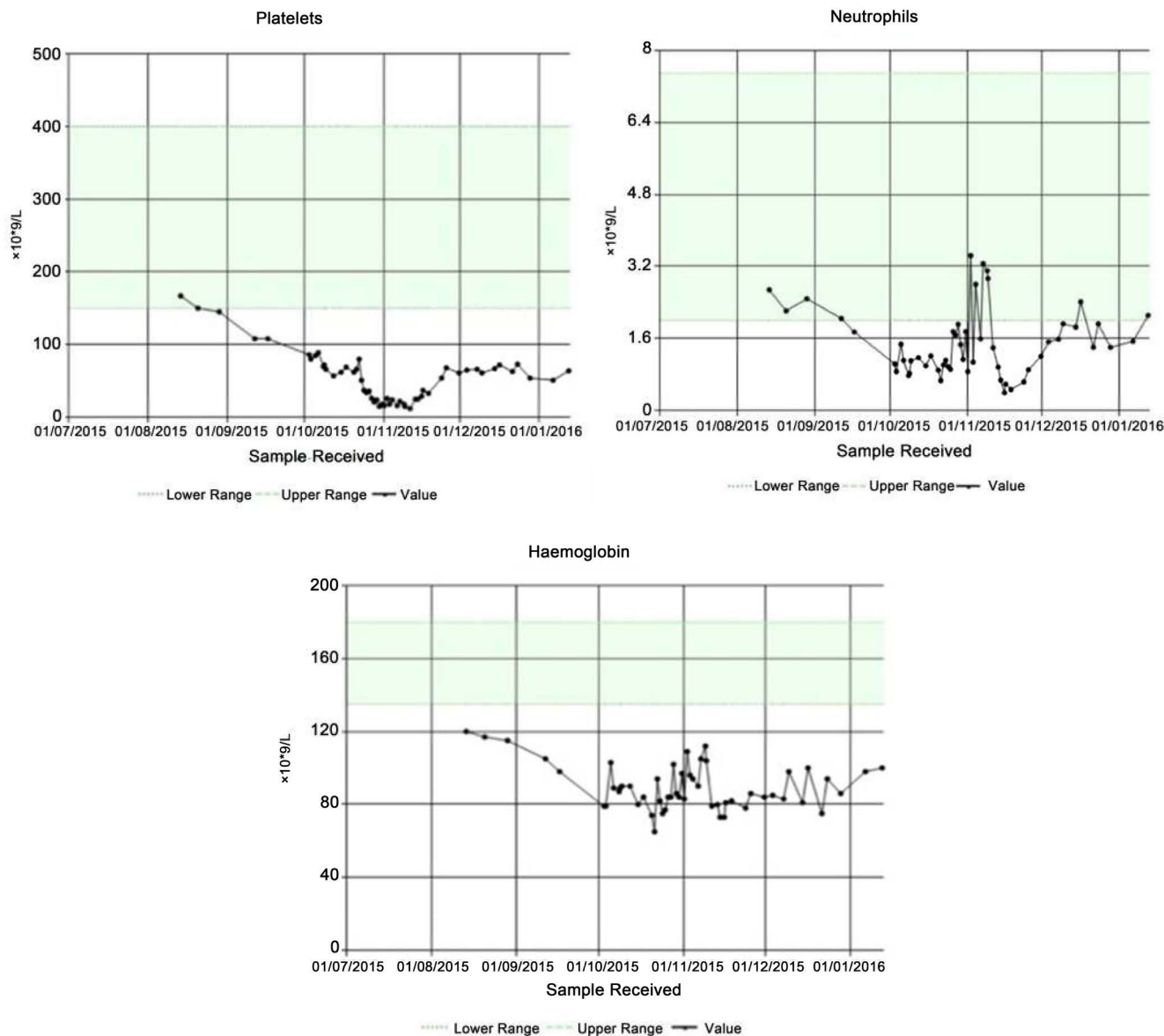


Figure 2. Demonstration of pancytopenia with subsequent improvement following IVIg and antibiotics.

Despite the initial improvement in blood counts, the patient has remained moderately pancytopenic following one year follow up with recurrent septic episodes and is currently being managed palliatively.

3. Discussion

HLH is a potentially fatal condition in which abnormal activation of the immune system results in haemophagocytosis, inflammation and tissue damage [6]. The underlying pathophysiology is not fully understood but involves an abnormal activation of the immune system, including macrophages, Natural Killer (NK) cells and cytotoxic lymphocytes [6] [7]. In particular, there is failure of normal auto-regulation of NK cell

function, increased activation and proliferation of lymphocytes and macrophages, and increased production of cytokines, which ultimately results in uncontrolled haemophagocytosis [6] [7].

Secondary HLH can occur in association with infections, most commonly viral infections, but has also been associated with fungal, parasitic and bacterial infections, including *Mycobacterium* species. Prompt identification of the underlying cause of HLH is important as it guides treatment decisions and early initiation of appropriate treatment reduces morbidity and mortality. Current treatment of primary HLH follows the HLH-2004 treatment protocol, which can also be beneficial for patients with secondary HLH [8] and consists of a combination of chemo-immunotherapy agents. However, in cases of secondary HLH in association with non-viral infections, targeted treatment involves anti-microbial and IVIg therapy [9].

Acquired HLH can pose a clinical conundrum for clinicians and rigorous investigation into past medical and surgical history can allude to the cause. Although *Mycobacterium* is a well-documented precipitant of haemophagocytosis, this is the first case documented in the literature with *M. chimaera* precipitated by an infected prosthetic valve. Prolonged broad-spectrum antibiotic therapy as well as IVIg can arrest the progression of HLH and improve pancytopenia.

References

- [1] Chamsi-Pasha, M.A.R., Alraies, M.C., Alraiyes, A.H. and His, E.D. (2013) *Mycobacterium avium* Complex-Associated Hemophagocytic Lymphohistiocytosis in a Sickle Cell Patient: An Unusual Fatal Association. *Case Reports in Hematology*, Article ID: 291518.
- [2] US Food and Drug Administration. Nontuberculous *Mycobacterium* Infections Associated with Heater-Cooler Devices: FDA Safety Communication. <http://www.fda.gov/MedicalDevices/Safety/AlertsandNotices/ucm466963.html>
- [3] Kohler, P., Kuster, S.P., Bloemberg, G., Schulthess, B., Frank, M., Tanner, F.C., *et al.* (2015) Healthcare-Associated Prosthetic Heart Valve, Aortic Vascular Graft, and Disseminated *Mycobacterium chimaera* Infections Subsequent to Open Heart Surgery. *European Heart Journal*, **36**, 2745-2753. <http://dx.doi.org/10.1093/eurheartj/ehv342>
- [4] Rosado, F.G.N. and Kim, A.S. (2013) Haemophagocytic Lymphohistiocytosis: An Update on Diagnosis and Pathogenesis. *American Journal of Clinical Pathology*, **139**, 713-727. <http://dx.doi.org/10.1309/AJCP4ZDKJ4ICOUAT>
- [5] Hui, Y.M.T., Pillinger, T., Luqmani, A. and Cooper, N. (2015) Haemophagocytic Lymphohistiocytosis Associated with *Mycobacterium tuberculosis* Infection. *BMJ Case Reports*.
- [6] Janka, G.E. and Lehmbery, K. (2013) Hemophagocytic Lymphohistiocytosis: Pathogenesis and Treatment. *ASH Education Book*, 605-611. <http://dx.doi.org/10.1182/asheducation-2013.1.605>
- [7] McClain, K. (2016) UpToDate®. Clinical Features and Diagnosis of Hemophagocytic Lymphohistiocytosis. <http://www.uptodate.com/contents/clinical-features-and-diagnosis-of-hemophagocytic-lymphohistiocytosis>
- [8] Hemophagocytic Lymphohistiocytosis Study Group. HLH (2004) Treatment Protocol of the Second International HLH Study 2004. <http://www.uni-ulm.de/expane/docs/HLH%202004%20Study%20Protocol.pdf>

- [9] Provan, D., Nokes, T.J.C., Agrawal, S., Winer, J.B. and Wood, P. Guidelines for the Use of Intravenous Immunoglobulin. Department of Health.
http://www.ivig.nhs.uk/documents/ivig_national_guideline.pdf



Scientific Research Publishing

Submit or recommend next manuscript to SCIRP and we will provide best service for you:

Accepting pre-submission inquiries through Email, Facebook, LinkedIn, Twitter, etc.

A wide selection of journals (inclusive of 9 subjects, more than 200 journals)

Providing 24-hour high-quality service

User-friendly online submission system

Fair and swift peer-review system

Efficient typesetting and proofreading procedure

Display of the result of downloads and visits, as well as the number of cited articles

Maximum dissemination of your research work

Submit your manuscript at: <http://papersubmission.scirp.org/>

Or contact ojbd@scirp.org

