



Diagnosis and Management of an Acquired Factor XIII Deficiency in a Limited Resource Setting: A Case Report

C C Kariyawan^{a++*}, P H D Athukorala^{a#}, N L Priyantha^{bt}
and B L T Balasuriya^{a‡}

^a Department of Haematology, Sri Jayewardenepura General Hospital, Thalpathpitiya, Nugegoda, Sri Lanka.

^b Pathology Laboratory, Sri Jayewardenepura General Hospital, Thalpathpitiya, Nugegoda, Sri Lanka.

Authors' contributions

This work was carried out in collaboration among all authors. All authors read and approved the final manuscript.

Article Information

DOI: <https://doi.org/10.9734/ahrj/2024/v7i4185>

Open Peer Review History:

This journal follows the Advanced Open Peer Review policy. Identity of the Reviewers, Editor(s) and additional Reviewers, peer review comments, different versions of the manuscript, comments of the editors, etc are available here: <https://www.sdiarticle5.com/review-history/127278>

Case Report

Received: 22/09/2024
Accepted: 25/11/2024
Published: 02/12/2024

ABSTRACT

Factor XIII deficiency, a rare bleeding disorder, can be either immune – mediated or non -immune and present significant challenges due to potential life-threatening bleeding. This report underscores the importance of targeted management in FXIII deficiency, particularly in low-resource setting where advanced testing may be inaccessible.

⁺⁺ Consultant Haematologist;

[#] Registrar in Haematology;

[†] Chief Medical Laboratory Technologist;

[‡] Medical Laboratory Technologist;

*Corresponding author: E-mail: chitrak64@yahoo.com;

Cite as: Kariyawan, C C, P H D Athukorala, N L Priyantha, and B L T Balasuriya. 2024. "Diagnosis and Management of an Acquired Factor XIII Deficiency in a Limited Resource Setting: A Case Report". *Asian Hematology Research Journal* 7 (4):224-28. <https://doi.org/10.9734/ahrj/2024/v7i4185>.

The case centers on 16-year-old boy with a history of mild bleeding who -presented with a subdural hemorrhage after a fall. Initial tests, including standard clotting profiles and screening for von Willebrand factor deficiency, were normal, prompting further investigation. A positive clot solubility test suggested Factor XIII deficiency. Due to limited facilities, FXIII assays were unavailable, so the patient was managed with fresh frozen plasma, cryoprecipitate, and tranexamic acid. Post-surgery bleeding revealed potential FXIII inhibitors, which were managed with additional plasma, cryoprecipitate, and oral prednisolone. The patient responded well and remained asymptomatic after discharge.

Keywords: Factor XIII deficiency; acquired factor XIII deficiency; bleeding disorders.

1. INTRODUCTION

“Acquired factor XIII (FXIII) deficiency is a rare bleeding disorder that can present with spontaneous or delayed life-threatening bleeding” [1,2]. “Causes of acquired deficiency maybe immune-mediated inhibition, or non-immune FXIII due to increased consumption or reduced synthesis” [3]. “The occurrence of acquired FXIII deficiency can be idiopathic or may be associated with comorbidities, such as malignancies or autoimmune disorders. Diagnosis of acquired FXIII deficiency and its underlying cause is important, as treatment options varies depending on the etiology” [4]. “Diagnosis requires quantitative FXIII testing in addition to supplementary inhibitor studies if the clinical situation suggests an immune-mediated pathophysiology” [4]. “Treatment may involve FXIII replacement, antifibrinolytic administration, and/or inhibitor eradication. However, exact treatment methods and accepted thresholds are not clearly defined in acquired FXIII deficiency” [5].

2. CASE PRESENTATION

A 16-year-old boy presented to the emergency department with an acute subdural hemorrhage (SDH) after a fall. As the patient had a past medical history of a bleeding tendency with a prolonged activated partial thromboplastin time (APTT) at 6 years of age the patient was referred to the haematology department for the investigation of a probable inherited bleeding disorder prior to surgery. He was a product of a consanguineous marriage however, there was no family history of a bleeding tendency.

His full blood count (FBC) revealed a white blood cell count (WBC) of $22 \times 10^9/L$, Hb of 13.4g/dl and platelet count of $277 \times 10^9/L$. The clotting profile

revealed a prothrombin time (PT) of 12.7 seconds(s) (11-13), APTT of 31.6s (28-34) and a thrombin time (TT) of 20.3s (18-24). His plasma fibrinogen level was 169.3 mg/dl (150- 400) and the bleeding time was 5.5 minutes (<7 minutes). Even though the above tests were normal, given the past history of a mild bleeding tendency a minor von Willebrand factor deficiency was ruled out.

Due to the normal findings of these tests, factor XIII deficiency was subsequently investigated. The clot solubility test, which is the screening test for factor XIII deficiency was performed and yielded a positive result. Since facilities for a factor XIII assay were unavailable and the patient required urgent surgery to evacuate the SDH, he was managed as a probable factor XIII deficiency case with fresh frozen plasma (FFP) at 15 to 20 ml/kg, cryoprecipitate at one bag per 10 kg, and tranexamic acid. Recombinant factor XIII products were not accessible in Sri Lanka. Surgery proceeded with no excessive bleeding during or after the procedure.

As the half- life of Factor XIII is around 15-19 days, a single dose of FFP and cryoprecipitate was anticipated to provide the required factor concentrate (5%) for a minimum of 4 weeks. However, increased bleeding into the surgical drain was noted on the third postoperative day, prompting reassessment with a repeat clot solubility test, which was prolonged. This raised the suspicion of factor XIII inhibitors, which has been known to be associated with trauma and worsens in head injury. The clot solubility test was then conducted using two tubes: one containing the patient’s plasma alone and another with the addition of 50% normal plasma. After 24 hours, the clot dissolved in both tubes, indicating the presence of a factor XIII inhibitor.

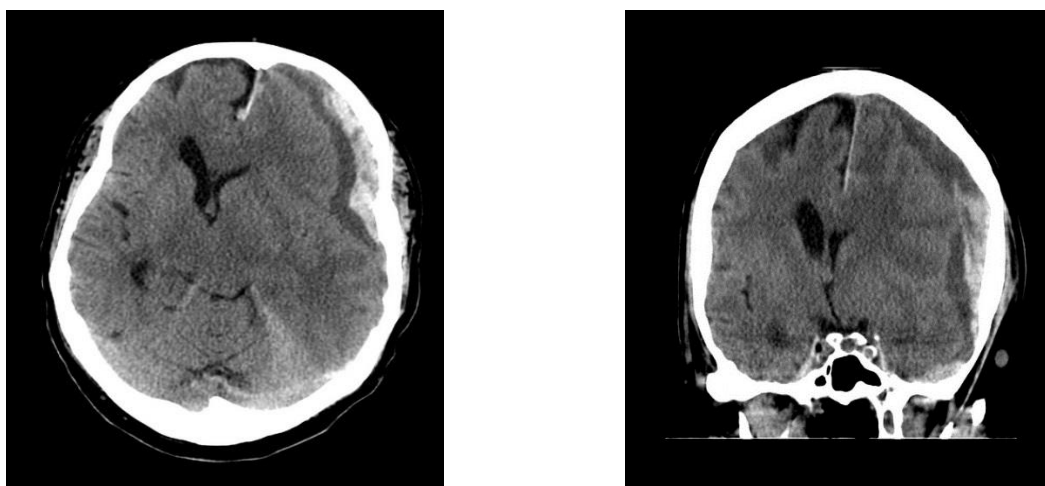


Fig. 1. Subdural hemorrhage

Treatment was administered with FFP and cryoprecipitate, along with inhibitor eradication using oral prednisolone at a dose of 1 mg/kg/day. A positive response was observed, with a reduction in bleeding, and the patient was discharged after five days of treatment. Prednisolone was gradually tapered over a two-week period. No further bleeding episodes occurred, and a follow-up clot solubility test performed three months later yielded a negative result. The patient remains asymptomatic to date.

3. DISCUSSION

“FXIII is the final factor in the coagulation cascade and plays a critical role in the stabilization of the clot by cross-linking fibrin and making the clot denser and firmer. Congenital FXIII deficiency is a rare bleeding disorder (1: 2,000,000) and is inherited as an autosomal recessive trait, with higher frequency in countries with consanguineous marriages. Severe inherited FXIII deficiency is characterized by delayed umbilical cord bleeding. Autoimmune FXIII deficiency is due to autoantibodies against FXIII subunits and can be secondary to autoimmune conditions such as systemic lupus erythematosus, rheumatoid arthritis, and malignancy” [6]. “Nonimmune causes include increased FXIII consumption due to massive surgical bleeding, disseminated intravascular consumption, or thrombosis or decreased FXIII synthesis such as in liver disease” [7,8].

“Diagnosis and treatment of acquired FXIII deficiency begins when the clotting profile is normal. It is necessary to measure FXIII activity

using a functional quantitative assay” [9]. “Evaluating FXIII deficiency requires specialized laboratory tests, including the clot solubility test, FXIII activity and antigen assay, inhibitor assay” [10,11]. “In confirmation of the factor XIII deficiency, there are two tests, one which is the chromogenic assay, which is the preferred first-line test to diagnose inherited or acquired FXIII deficiency” [12]. “It is appropriate for evaluation of individuals with a bleeding disorder when routine clotting tests, platelet count and function are normal, to monitor treatment in individuals being treated for FXIII deficiency and confirm abnormalities identified in the qualitative FXIII assay (clot solubility test)” [13]. “The other which is a qualitative solubility assay and is most useful if severe FXIII deficiency is suspected (<1% of normal activity), to distinguish between FXIII deficiency and a FXIII inhibitor. Abnormal results should be confirmed with quantitative testing” [14].

“Options for FXIII replacement include highly purified plasma-derived FXIII concentrate (Corifact/Fibrogammin P) and recombinant FXIII-A2 concentrate (Tretten)” [15]. “If FXIII concentrates are not readily available, cryoprecipitate and FFP may be used. Cryoprecipitate is produced from FFP and contains a higher concentration of FXIII (~3 IU mL⁻¹) compared with that of FFP (1 IU mL⁻¹)” [16]. “Cryoprecipitate contains approximately 20% to 30% of the original quantity of FXIII as plasma. The average content of FXIII in FFP varies between 0.5 and 1.5 U/mL. Compared to FFP, cryoprecipitate has a higher enrichment of FXIII. However, 1 bag of cryoprecipitate yields lower than that of a bag of FFP. Therefore, FFP

may be preferred when infusion volume is not a significant consideration” [16].

“Treatment of acquired FXIII deficiency secondary to autoantibodies includes autoantibody eradication by immunosuppressive therapy or removal by plasma exchange with immune-adsorption. Mild inhibitors may respond to steroid therapy alone, while more potent inhibitors may necessitate B-cell-directed therapy such as rituximab” [17]. “In an acute bleed the treatment goal is to attain FXIII activity levels greater than 5%. Higher targets may be required for severe, life-threatening bleeding episodes. A single dose of replacement product is typically sufficient to achieve therapeutic objectives” [18]. “The dosing for patients experiencing acute bleeding is outlined as follows: Recombinant FXIII-A subunit: 35 IU/kg, Plasma-derived FXIII concentrate: Corifact 40 IU/kg; Fibrogammin and Fibrogammin-P 10 to 20 IU/kg, FFP 15 to 20 mL/kg, Cryoprecipitate: 1 bag per 10 kg along with inhibitor eradication. Our patient was successfully managed according to the accepted guidelines but with minimal testing and treatment facilities” [19,20,21].

4. CONCLUSION

This case highlights the complexities of managing acute bleeding and surgery in patients with suspected acquired bleeding disorders and potential inhibitor formation. Prompt diagnosis, factor XIII replacement, and immunosuppression with corticosteroids can lead to successful outcomes, even in resource-constrained settings.

ETHICAL APPROVAL

As per international standards or university standards written ethical approval has been collected and preserved by the author(s).

CONSENT

As per international standards, parental written consent has been collected and preserved by the author(s).

DISCLAIMER (ARTIFICIAL INTELLIGENCE)

Author(s) hereby declare that NO generative AI technologies such as Large Language Models (ChatGPT, COPILOT, etc.) and text-to-image

generators have been used during the writing or editing of this manuscript.

COMPETING INTERESTS

Authors have declared that no competing interests exist.

REFERENCES

1. L Esteban M, M Carbonell M, V Soler J, D Martin JL, Duque P, P Izquierdo C. Acquired Factor XIII Deficiency Is Associated with High Morbidity and Mortality in Critically Ill Patients.. 140, Blood. 2022;1422–4.
2. Mercado MR, Cozzarelli S V, C Cabrera C, Vázquez RN, Bárcenas RJ, Garrido RP,. Factor XIII Deficiency As Underlying Cause Of Unexplained Bleeding. 122, Blood. 2013;4776–4776.
3. Malkhassian D, Sabir S, Sharma S. Physiology, Factor XIII.
4. Yan MTS, Rydz N, Goodyear D, Sholzberg M. Acquired factor XIII deficiency: A review. Transfus Apher Sci. 2018; 57(6):724–30.
5. Duranteau O, Tatar G, Demulder A, Tuna T. Acquired factor XIII deficiency. 2, European Journal of Anaesthesiology Intensive Care. 2023;e0035.
6. Marco A, Marco P. Autoimmune acquired factor XIII deficiency: A case report. J Blood Med. 2021;12:63–8.
7. Kleber C, Sablotzki A, Casu S, Olivieri M, Thoms KM, Horter J, The impact of acquired coagulation factor XIII deficiency in traumatic bleeding and wound healing. Crit Care: Available:https://doi.org/10.1186/s13054-022-03940-2
8. Hetz M, Juratli T, Tiebel O, Giesecke MT, Tsitsilonis S, Held HC, Acquired Factor XIII Deficiency in Patients with Multiple Trauma. Injury. 2023;54(5):1257–64. Available:https://doi.org/10.1016/j.injury.2022.12.021
9. Duranteau O, Tatar G, Demulder A, Tuna T. Acquired factor XIII deficiency. Eur J Anaesthesiol Intensive Care. 2023;2(5):e0035.
10. Karimi M, Peyvandi F, Naderi M, Shapiro A. Factor XIII deficiency diagnosis:

- Challenges and tools. *Int J Lab Hematol.* 2018;40(1):3–11.
11. Dorgalaleh A, Tabibian S, Hosseini S, Shamsizadeh M. Guidelines for laboratory diagnosis of factor XIII deficiency. *Blood Coagul Fibrinolysis.* 2016;27(4):361–4.
 12. Kohler HP, Ichinose A, Seitz R, Ariens RAS, Muszbek L. Diagnosis and classification of factor XIII deficiencies. *J Thromb Haemost.* 2011;9(7):1404–6. Available: <https://doi.org/10.1111/j.1538-7836.2011.04315.x>
 13. Dorgalaleh A, Tabibian S, Hosseini MS, Farshi Y, Roshanzamir F, Naderi M. Diagnosis of factor XIII deficiency. *Hematology.* 2016;21(7):430–9.
 14. Amano S, Oka K, Sato Y, Sano C, Ohta R. Measuring Factor XIII Inhibitors in Patients with Factor XIII Deficiency: A Case Report and Systematic Review of Current Practices in Japan. *J Clin Med.* 2022;11(6).
 15. Wakabayashi N, Nishioka H, Yuzuriha S. Recurrent Bleeding after Head Trauma Caused by Acquired Factor XIII Deficiency. *Plast Reconstr Surg - Glob Open.* 2022;10(2):E4109.
 16. Caudill JSC, Nichols WL, Plumhoff EA, Schulte SL, Winters JL, Gastineau DA, Comparison of coagulation factor XIII content and concentration in cryoprecipitate and fresh-frozen plasma. *Transfusion.* 2009;49(4):765–70.
 17. Dolnicar MB, Rajic V, Kitanovski L, Debeljak M. Rituximab for the treatment of high titre inhibitors in mild haemophilia A. *Blood Transfus.* 2014;12(SUPPL.1):345–7.
 18. Mangla A, H Hamad RBKAK. Factor XIII deficiency. 14, Factor XIII Deficiency. StatPearls Publishing; 2024;1190–200.
 19. Iyengar V, Montcrieff C, Pels S. Patient-centered approach to managing factor XIII deficiency. *BMJ Case Rep.* 2021;14(9): 1–3.
 20. Zanon E, Pasca S, Sottillotta G, Molinari AC, Ferretti A, Di Gregorio P. A multicenter, real-world experience with recombinant FXIII for the treatment of patients with FXIII deficiency: from pharmacokinetics to clinical practice. The Italian FXIII Study. *Blood Transfus.* 2023; 21(4):350–5.
 21. Wakabayashi N, Nishioka H, Yuzuriha S. Recurrent bleeding after head trauma caused by acquired factor XIII deficiency. *Plastic and Reconstructive Surgery–Global Open.* 2022 Feb 1;10(2):e4109.

Disclaimer/Publisher's Note: The statements, opinions and data contained in all publications are solely those of the individual author(s) and contributor(s) and not of the publisher and/or the editor(s). This publisher and/or the editor(s) disclaim responsibility for any injury to people or property resulting from any ideas, methods, instructions or products referred to in the content.

© Copyright (2024): Author(s). The licensee is the journal publisher. This is an Open Access article distributed under the terms of the Creative Commons Attribution License (<http://creativecommons.org/licenses/by/4.0>), which permits unrestricted use, distribution, and reproduction in any medium, provided the original work is properly cited.

Peer-review history:

The peer review history for this paper can be accessed here:

<https://www.sdiarticle5.com/review-history/127278>