



A Fatal Presentation of Primary Cutaneous Mucormycosis in an Immunocompetent Adult

Poojitha Yalla^{1*}, Saumya Bhagat¹, L. Badareesh¹ and Mary Mathew²

¹Department of Surgery, Kasturba Medical College, Manipal Academy of Higher Education, Manipal, 576104, India.

²Department of Pathology, Kasturba Medical College, Manipal Academy of Higher Education, Manipal, 576104, India.

Authors' contributions

This work was carried out in collaboration among all authors. Authors PY, LB and SB designed the case report, were involved in the management of the case and wrote the first draft of the manuscript. Author MM did the histopathological analyses of the case. Authors PY and SB managed the literature searches. All authors read and approved the final manuscript.

Article Information

Editor(s):

(1) Dr. N. S. Kannan, Melmaruvathur Athi Paraskthi Institute of Medical Sciences & Research, Tamil Nadu M.G.R. Medical University, India.

Reviewers:

(1) Massimo Berger, University of Turin, Italy.

(2) Sj Carlan, USA.

Complete Peer review History: <http://www.sdiarticle4.com/review-history/54846>

Case Study

Received 14 December 2019

Accepted 22 February 2020

Published 29 February 2020

ABSTRACT

Background: Mucormycosis is an opportunistic fungal infection, affecting immunosuppressed hosts. Infection in an immunocompetent individual is uncommon, with varying degrees of severity. Usual clinical presentations include rhinocerebral and pulmonary mucormycosis, with cutaneous, gastrointestinal and disseminated forms being less common.

Case Report: A 68-year-old immunocompetent adult, presented with acute onset non-traumatic large necrotizing wound over the right thigh, after receiving initial treatment at a primary center for 2 weeks. On evaluation, the patient was found to be in early sepsis, and emergency extensive debridement was done with the continuation of IV antibiotics. Fungal cultures were suggestive of Mucormycosis and treatment initiated with systemic and topical antifungal agents, despite which the patient continued to deteriorate with acute renal failure and eventually succumbed to the sepsis.

Conclusion: High clinical suspicion and apt investigations are essential to initiate the appropriate antifungal therapy and to prevent life-threatening invasive infection.

*Corresponding author: E-mail: poojithayalla@hotmail.com;

Keywords: Cutaneous mucormycosis; immunocompetent; soft tissue infections; renal disease.

1. INTRODUCTION

Mucormycosis is a fungal infection caused by opportunistic fungi, Mucorales. They are often found in mouldy vegetation and soil. Humans get infected from entry via the respiratory or gastrointestinal tract or through traumatised skin. The majority (80%) of incidents occur in immunosuppressed hosts, and infection of the immunocompetent host is rare. Cutaneous mucormycosis is the third most commonly occurring type; half of these are in immunocompetent hosts [1]. The clinical presentation is vague, a common finding being a plaque with surrounding induration, rapidly progressing to necrosis, affecting the skin, subcutaneous layers and occasionally fascia and even the muscles beneath. The importance of prompt diagnosis needs to be emphasised, as it is an invasive life-threatening disease.

2. CASE REPORT

A 68-year-old farmer, presented to the emergency room with a large wound over the anterior aspect of his right thigh.

Two weeks prior, he developed a sudden diffuse swelling of the right thigh that rapidly progressed without a history of trauma or insect bite to the area. There was also no history of steroid use or

diabetes. He was evaluated at a primary health center, and was diagnosed with compartment syndrome and an emergency fasciotomy was done, a 15 cm long incision given on the anterior aspect of the right thigh, extending up to the deep fascia, which was incised the underlying muscle was exposed, and necrotic subcutaneous tissue was excised. Broad-spectrum intravenous antibiotics were started. The patient underwent repeated extensive debridement over 2 weeks, and multiple wound cultures sent showed no bacterial growth. Antibiotics were stepped up to Piperacillin-Tazobactam, despite which the wound remained unhealthy with extensive slough and he had persistent pyrexia with rising total counts. Hence, he was referred to our tertiary health care centre, for further management.

On arrival, the patient was febrile, tachycardic and in altered sensorium. He had a large irregular 25 x 15 cm wound over the anterior aspect of right thigh, with exposed and necrotic anterior compartment muscles, and extensive slough (Fig. 1), with cellulitis extending from the groin crease up to the knee without any evidence of arterial insufficiency. Laboratory investigations showed marked leukocytosis with left shift, hyponatremia and deranged renal function parameters. An X-ray of the lower limb was done, which showed no involvement of the underlying bone, and showed subcutaneous air.

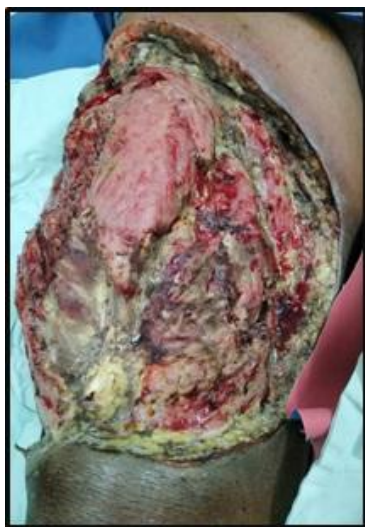

Fig. 1. At presentation, necrotizing wound with extensive slough

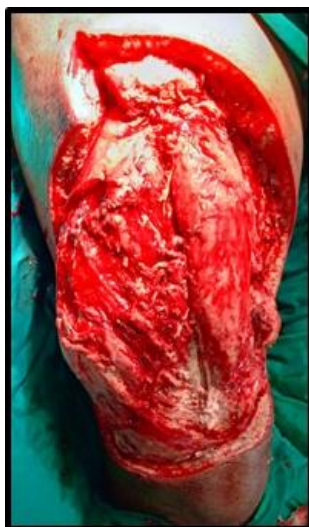

Fig. 2. Post debridement, wound appearing healthy

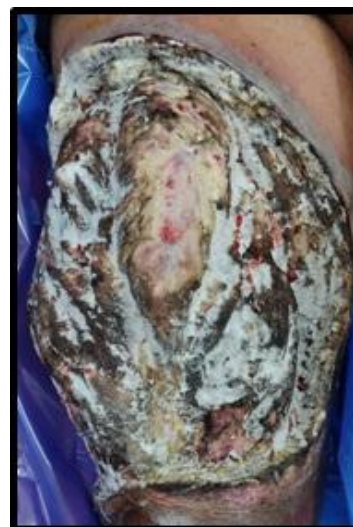

Fig. 3. Postoperative day 1, showing extensive cottony growth

In view of extensive myonecrosis with sepsis and acute kidney injury (AKI), he underwent extensive debridement (Fig. 2). Tissue was sent for culture and histopathological examination.

On the first post-operative day, the wound was unhealthy with blackish discoloration and cottony growth over the tissues (Fig. 3). A bedside impression smear was taken from the wound and fungal staining on KOH mount was done, which showed abundant, broad, hyaline, sparsely septate, filamentous fungal hyphae, suggestive of mucormycosis. As patient's condition continued to worsen, the institution's clinical microbiology team started systemic liposomal Amphotericin B – 370 mg IV given 24th hourly (5 mg/kg/d) and the local application of Amphotericin powder along with Terbinafine ointment. Even then both wound and the general condition of the patient kept deteriorating with fulminant sepsis, AKI, & refractory hyperkalemia (for which hemodialysis was done). In spite of all measures, he succumbed, on the sixth postoperative day. The final culture report was suggestive of *Rhizopus oryzae*. Histopathological examination of the tissue was suggestive of myonecrosis with mucormycosis (Fig. 4).

3. DISCUSSION

Mucormycosis is an emergent invasive fungal infection caused by opportunistic fungi of the phylum Glomeromycota. The various clinical presentations are rhinocerebral, pulmonary and cutaneous mucormycosis, with gastrointestinal and disseminated forms being less common. Majority of the clinical isolates belong to the genera *Rhizopus*, with *Rhizopus oryzae*, *Lichtheimia corymbifera* and *Apophysomyces elegans* being the strains frequently isolated in cutaneous mucormycosis [1,2].

In a prospective multicentre study on mucormycosis in India, 9.5 % of cases presented as cutaneous mucormycosis, although the actual incidence both in India and worldwide is unknown [3]. The typical risk factors are uncontrolled diabetes, and immunosuppression due to HIV infection or haematological malignancies and allogenic hematopoietic stem cell or solid organ transplantation [4,5]. Cutaneous mucormycosis may be either primary, where there is direct inoculation of the spores into the dermis, or secondary where there is spread of infection from another location [3,6].

Primary cutaneous mucormycosis can be localized, deep or disseminated, and may have a gradual onset or a fulminant presentation. The wound usually appears as cellulitis with necrosis, with the dissemination and deep tissue involvement being unusual complications. It is usually mistaken for the more common synergistic gangrene due to bacterial infection and needs to be kept in mind while working up such patients if there is a rapid progression with no response to antibiotics.

Timely identification of the fungus is essential to establish an early antifungal treatment. The diagnosis depends upon histopathological identification of organisms in tissue with confirmation by cultures. A KOH mount examination usually shows hyaline, non-septated, hyphae 5µm wide and 20 to 50µm long, with irregular right-angled branching, predominantly at the periphery of the lesion. Fungal cultures are done in Sabouraud and potato dextrose agar media to isolate the causative strain and are positive in about 72% to 89% of cutaneous mucormycosis [1,4]. Histopathological identification of thick, hyaline, non-septated and bifurcated hyphae on hematoxylin and eosin staining has an added advantage while diagnosing primary cutaneous mucormycosis. However, these features are non-specific and similar to infection with other filamentous fungi as well; hence need to be interpreted in conjunction with culture reports [1,6]. At present, novel molecular diagnostic tools are being developed, for accurate identification of the fungus. A single tube multiplex real-time PCR that identifies the genus *Mucor*, *R. oryzae* and *R. microsporus* from samples, and gives results in 2 to 3 hours, with a 100% specificity, has been developed by Bernal-Martinez et al. [7].

Prompt treatment with extensive surgical debridement, appropriate antifungal therapy, and treatment of the primary condition like uncontrolled diabetes and temporary tapering and cessation of any ongoing immunosuppressant therapy, is necessary, to prevent fatal complications. The first-line management of choice is monotherapy with amphotericin B or its lipid formulations which being less nephrotoxic can be used for longer periods with higher doses [8]. Other agents that are used as second-line therapy include azole derivatives – Posaconazole and Isavuconazole. The latter is a recently approved drug for invasive mucormycosis [9,10]. Mortality due to

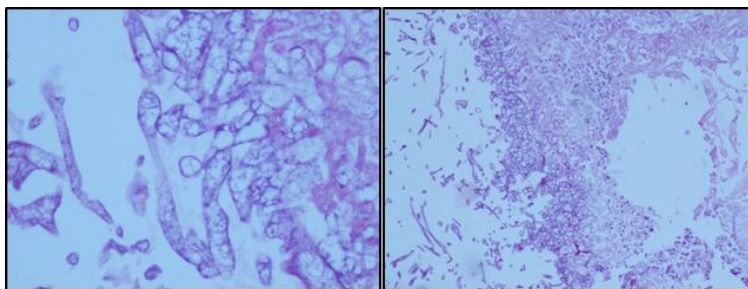


Fig. 4. Histopathological examination

cutaneous mucormycosis is less than that due to other presentations of mucormycosis, with deep invasive cutaneous mucormycosis having a higher mortality rate, ranging from 26% to 43 % [1,4]. Risk factors associated with higher mortality included disseminated disease and associated renal failure. Hence early recognition and treatment are important to prevent these complications to develop.

4. CONCLUSION

In our case, the delay of 2 weeks, to reach the final diagnosis, owing to the rarity of the presentation and failure to suspect a cause other than the common bacterial synergistic gangrene, in a non- diabetic individual, without history of trauma or insect bite, was a main factor leading to the fatal prognosis of the patient. The possible source of infection being exposure to the spores in the vegetation and soil. Another possibility is a secondary infection of the wound, due to contaminated hospital dressings. Hence, it cannot be emphasised enough, that a high clinical suspicion and appropriate timely investigations are necessary, to reach a diagnosis and the importance of initiating treatment based on clinical findings and suspicion, awaiting culture reports is paramount.

CONSENT

Informed consent was obtained from all individual participants included in the study.

ETHICAL APPROVAL

As per international standard or university standard written ethical approval has been collected and preserved by the author(s).

COMPETING INTERESTS

Authors have declared that no competing interests exist.

REFERENCES

1. Skiada A, Rigopoulos D, Larios G, Petrikkos G, Katsambas A. Global epidemiology of cutaneous zygomycosis. *Clin Dermatol.* 2012;30(6):628-32. DOI: 10.1016/j.clindermatol.2012.01.010
2. Rammaert B, Lanternier F, Zahar JR, Dannaoui E, Bougnoux ME, Lecuit M, et al. Healthcare-associated mucormycosis. *Clin Infect Dis.* 2012;54(Suppl1):S44-54. DOI: 10.1093/cid/cir867
3. Prakash H, Ghosh AK, Rudramurthy SM, Singh P, Xess I, et al. A prospective multicenter study on mucormycosis in India: Epidemiology, diagnosis and treatment. *Medical Mycology.* 2019;57(4): 395–402. DOI: <https://doi.org/10.1093/mmy/myy060>
4. Roden MM, Zaoutis TE, Buchanan WL, Knudsen TA, Sarkisova TA, Schaufele RL, et al. Epidemiology and outcome of zygomycosis: A review of 929 reported cases. *Clin Infect Dis.* 2005;41(5):634-53. Epub 2005 Jul 29.
5. Skiada A, Pagano L, Groll A, Zimmerli S, Dupont B, Lagrou K, et al. Zygomycosis in Europe: Analysis of 230 cases accrued by the registry of the European Confederation of Medical Mycology (ECMM) Working Group on Zygomycosis between 2005 and 2007. *Clin Microbiol Infect.* 2011;17(12):1859-67. Epub 2011 Jul 1. DOI: 10.1111/j.1469-0691.2010.03456.x
6. Bonifaz A, Vázquez-González D, Tirado-Sánchez A, Ponce-olivera RM. Cutaneous zygomycosis. *Clin Dermatol.* 2012;30(4): 413-9. DOI:10.1016/J.CLINDERMATOL.2011.09. 013
7. Bernal-Martínez L, Buitrago MJ, Castelli MV, Rodríguez-Tudela JL, Cuenca-Estrella M. Development of a single tube multiplex real-time PCR to detect the most clinically relevant mucormycetes species. *Clin*

- Microbiol Infect. 2013;19(1):E1-E7. Epub 2012 Aug 28.
DOI: 10.1111/j.1469-0691.2012.03976.x
8. Shoham S, Magill SS, Merz WG, Gonzalez C, Seibel N, Buchanan WL, et al. Primary treatment of zygomycosis with liposomal amphotericin B: Analysis of 28 cases. *Med Mycol*. 2010;48(3):511-7.
DOI: 10.3109/13693780903311944
9. Peel T, Daffy J, Thursky K, Stanley P, Buising K. Posaconazole as first line treatment for disseminated zygomycosis. *Mycoses*. 2008;51:5425.
DOI: 10.1111/J.1439-0507.2008.01499.X
10. McCormack PL. Isavuconazonium: First global approval. *Drugs*. 2015;75(7):817-22.
DOI: 10.1007/s40265-015-0398-6

© 2020 Yalla et al.; This is an Open Access article distributed under the terms of the Creative Commons Attribution License (<http://creativecommons.org/licenses/by/4.0>), which permits unrestricted use, distribution, and reproduction in any medium, provided the original work is properly cited.

Peer-review history:
The peer review history for this paper can be accessed here:
<http://www.sdiarticle4.com/review-history/54846>